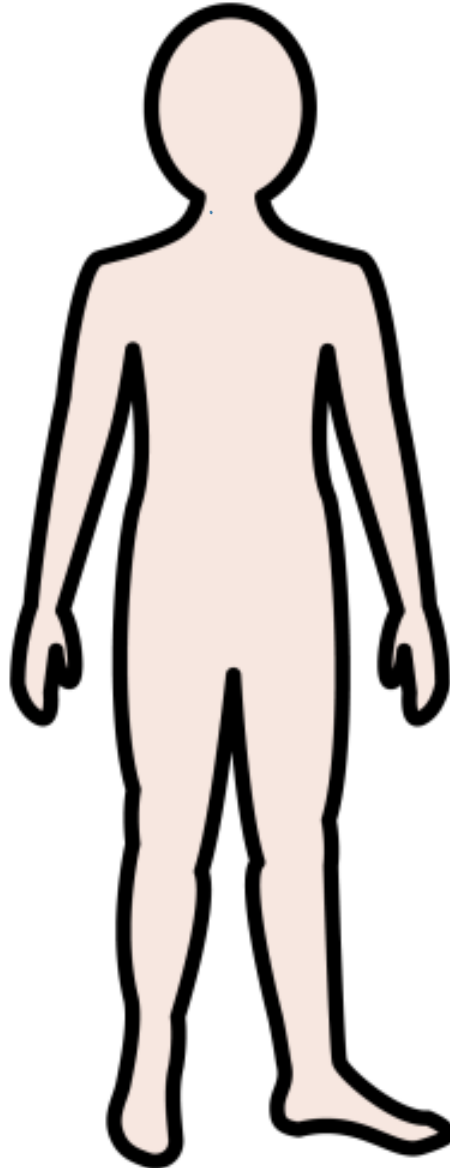


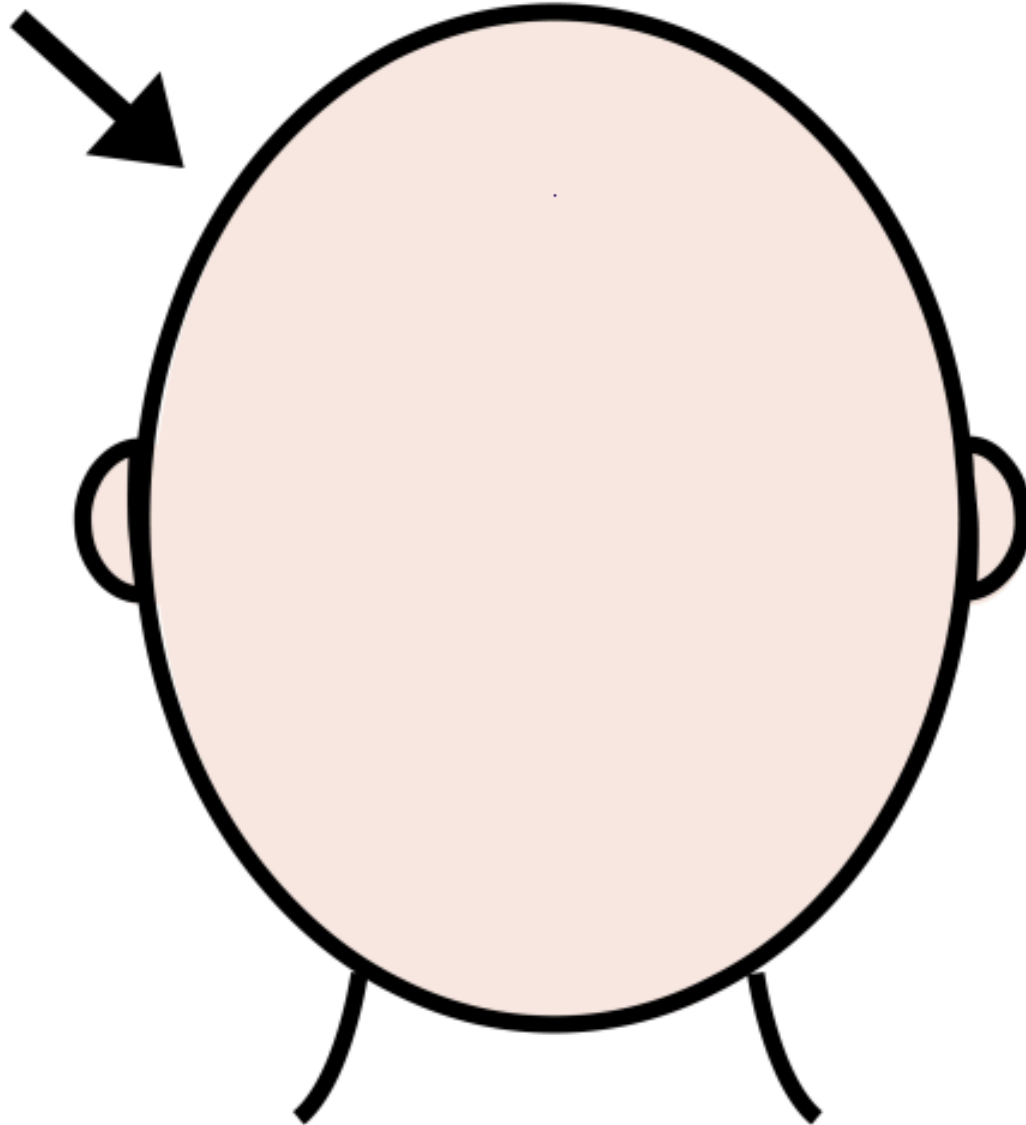
Lo schema  
corporeo

# LE PARTI DEL CORPO


# IL CORPO




# LA TESTA




# IL VOLTO



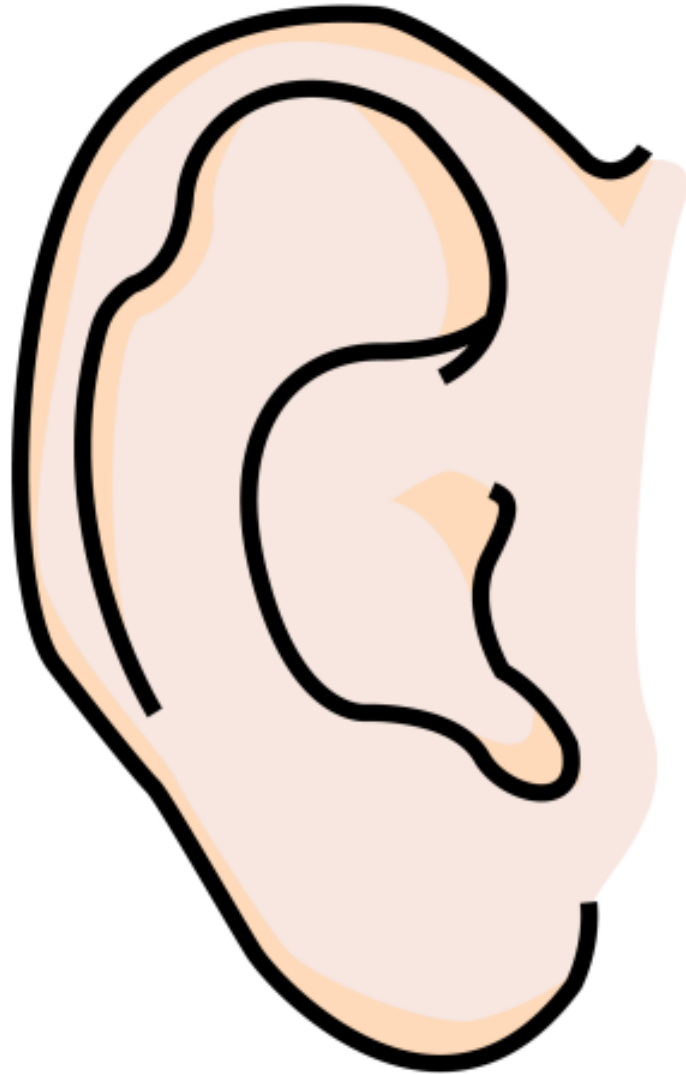
# I CAPELLI



# LA FRONTE

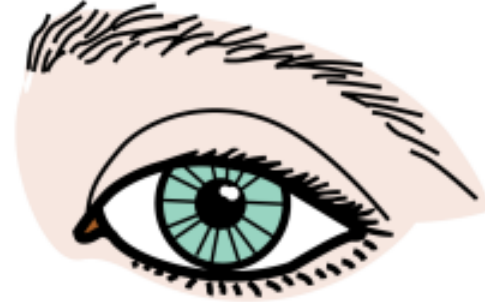
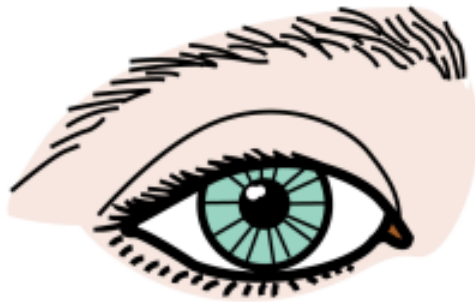
# L'ORECCHIO






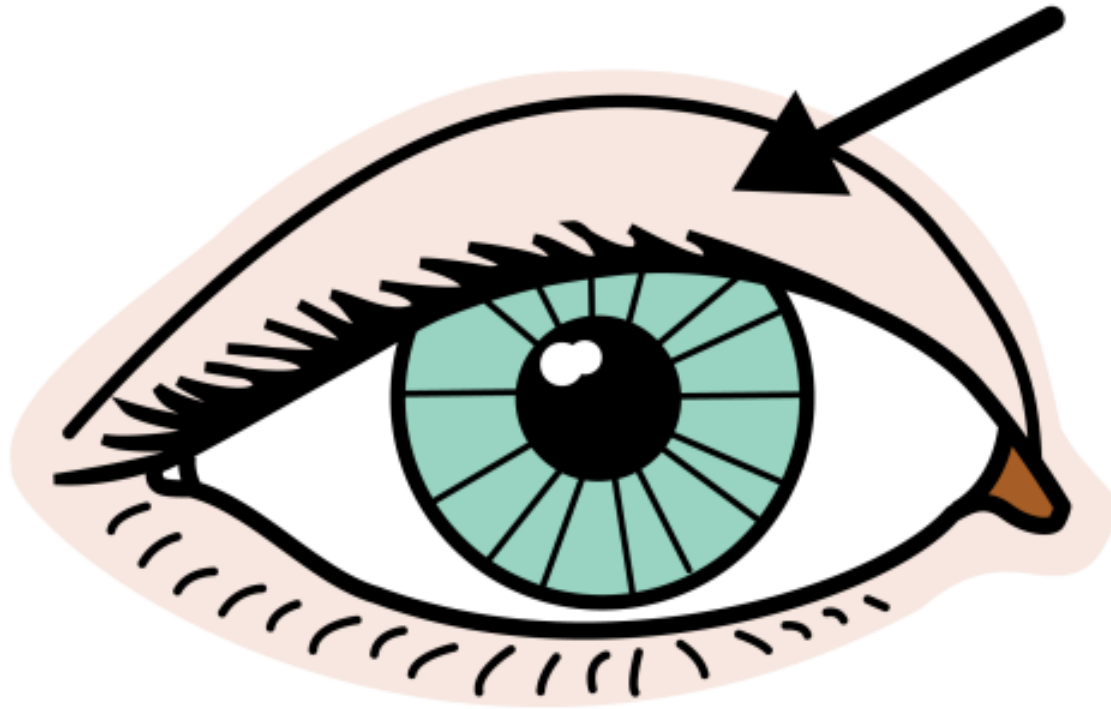
# GLI OCCHI



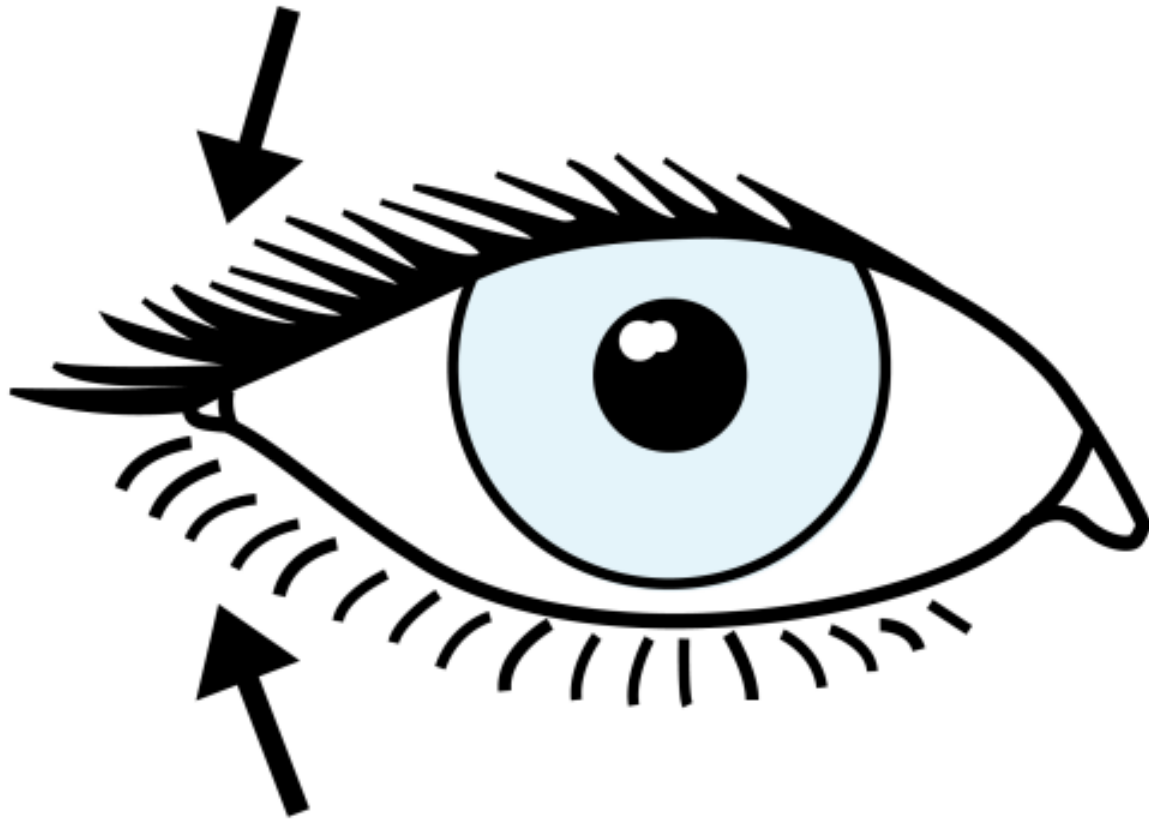
# IL SOPRACCIGLIO



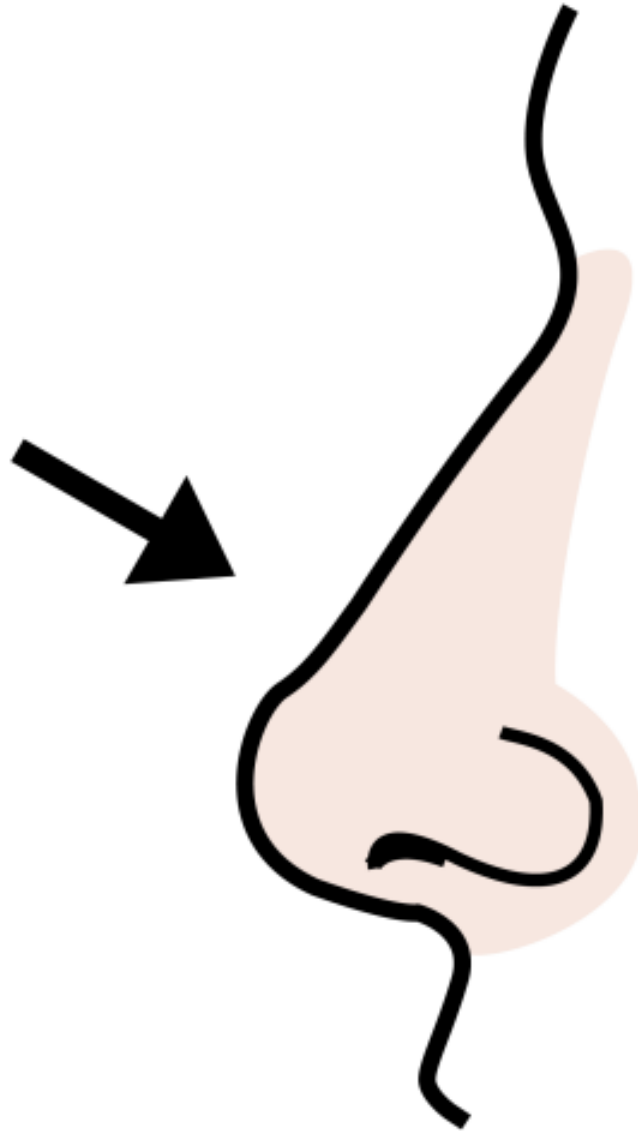
# parpado



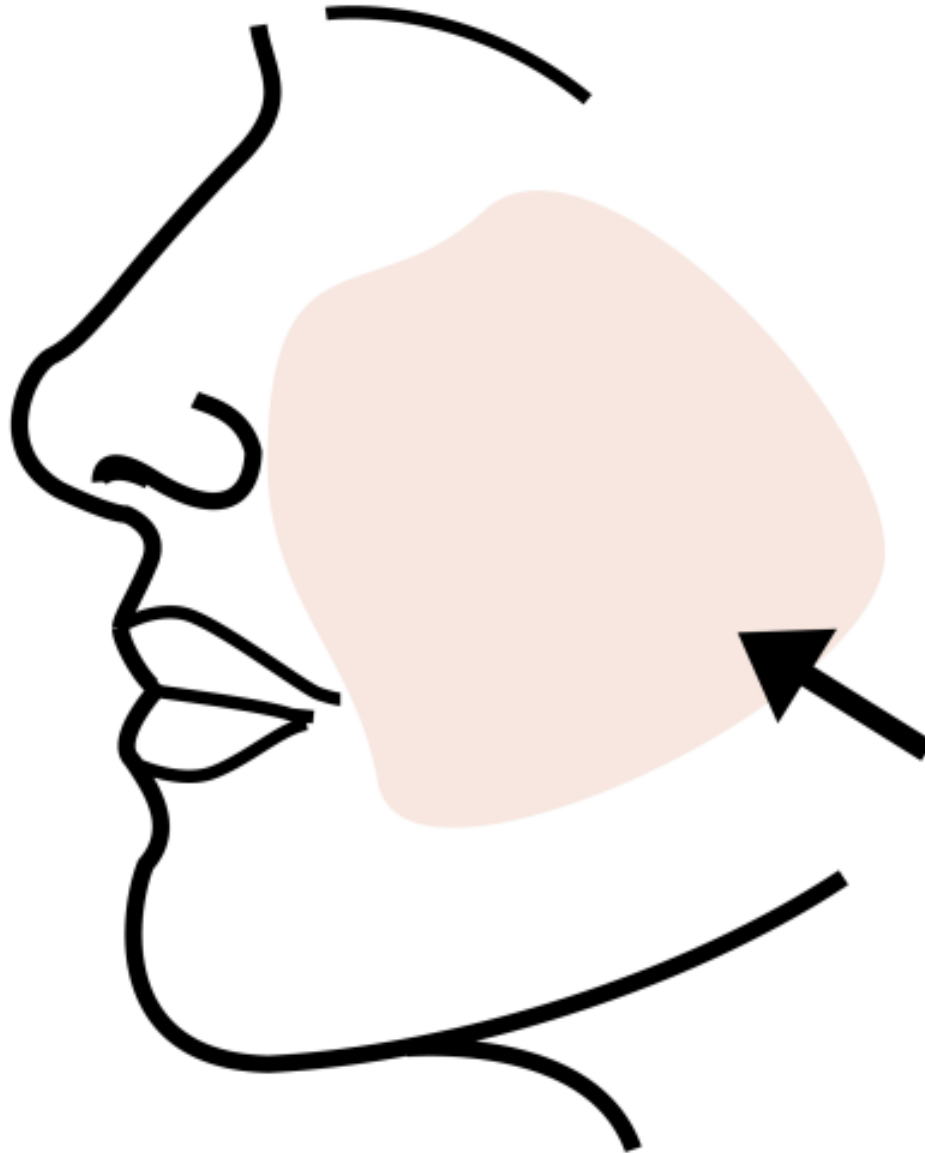
# LE CIGLIA



# IL NASO




# LA GUANCIA



# LA BOCCA

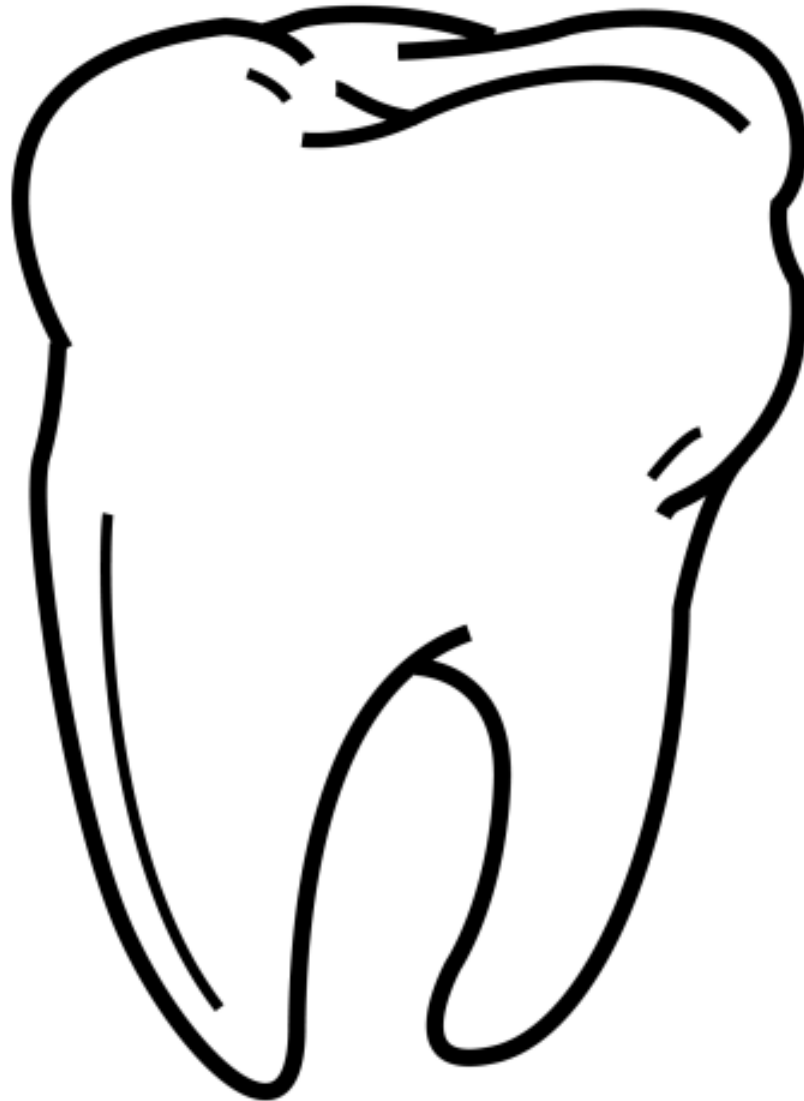


# LA LINGUA






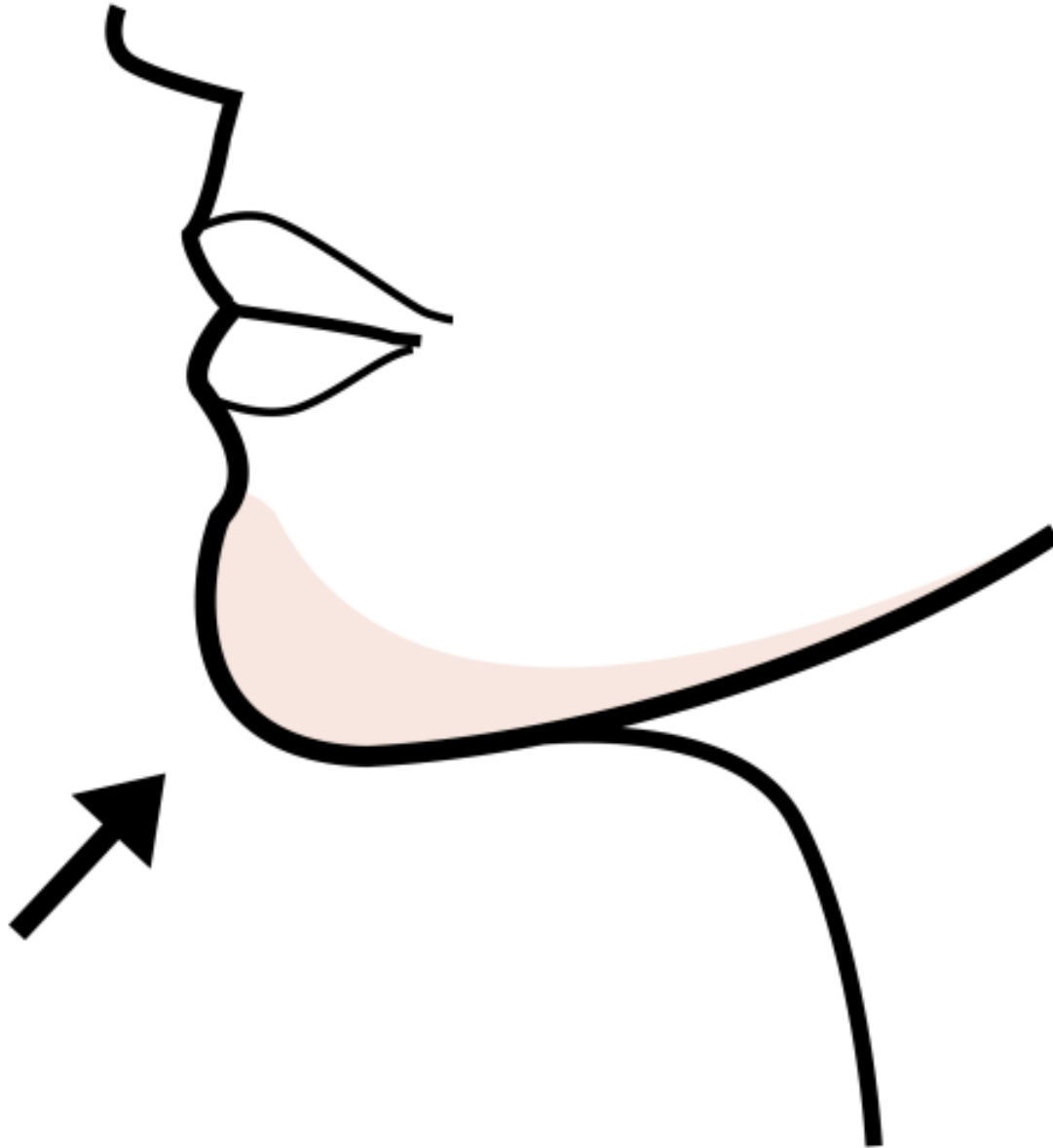
# IL DENTE



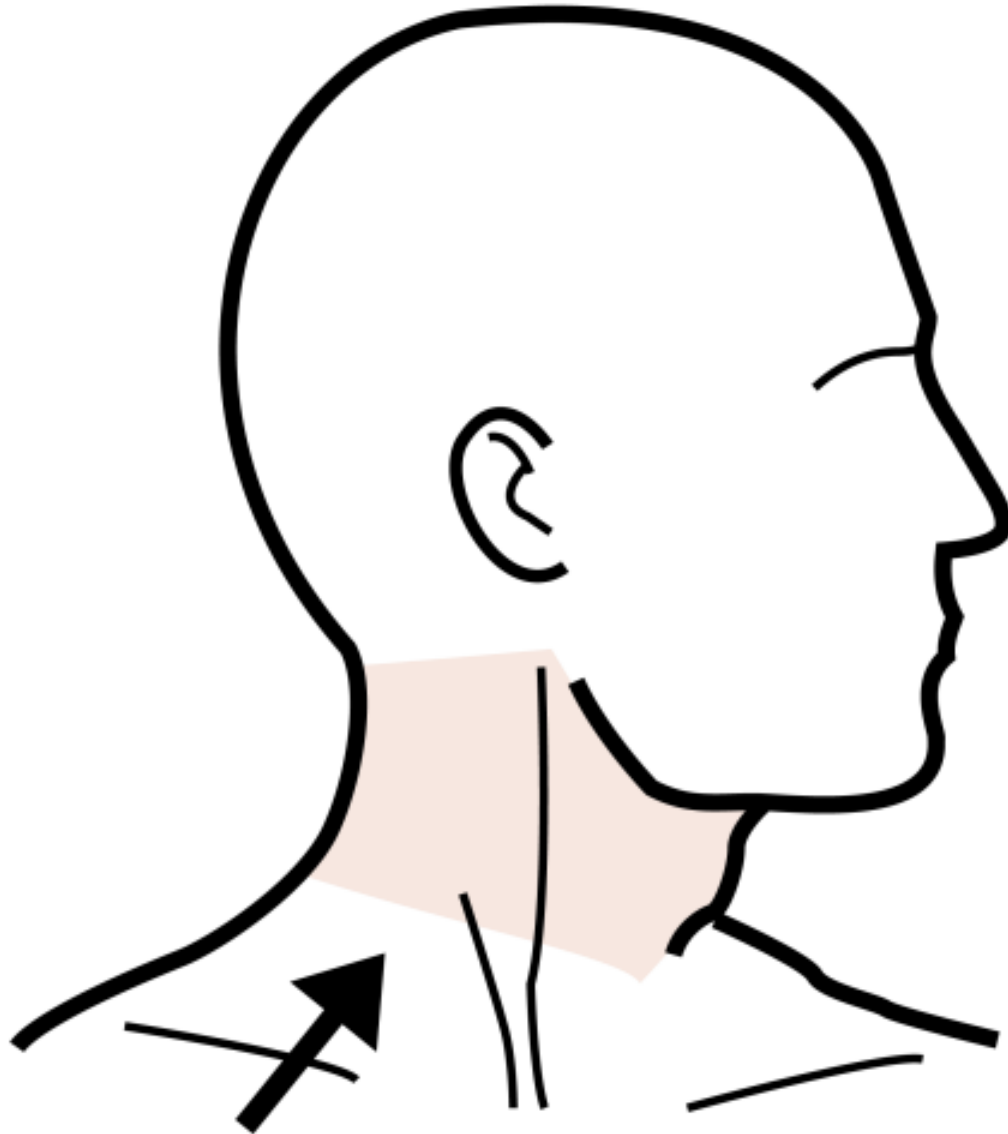
# LE LABBRA



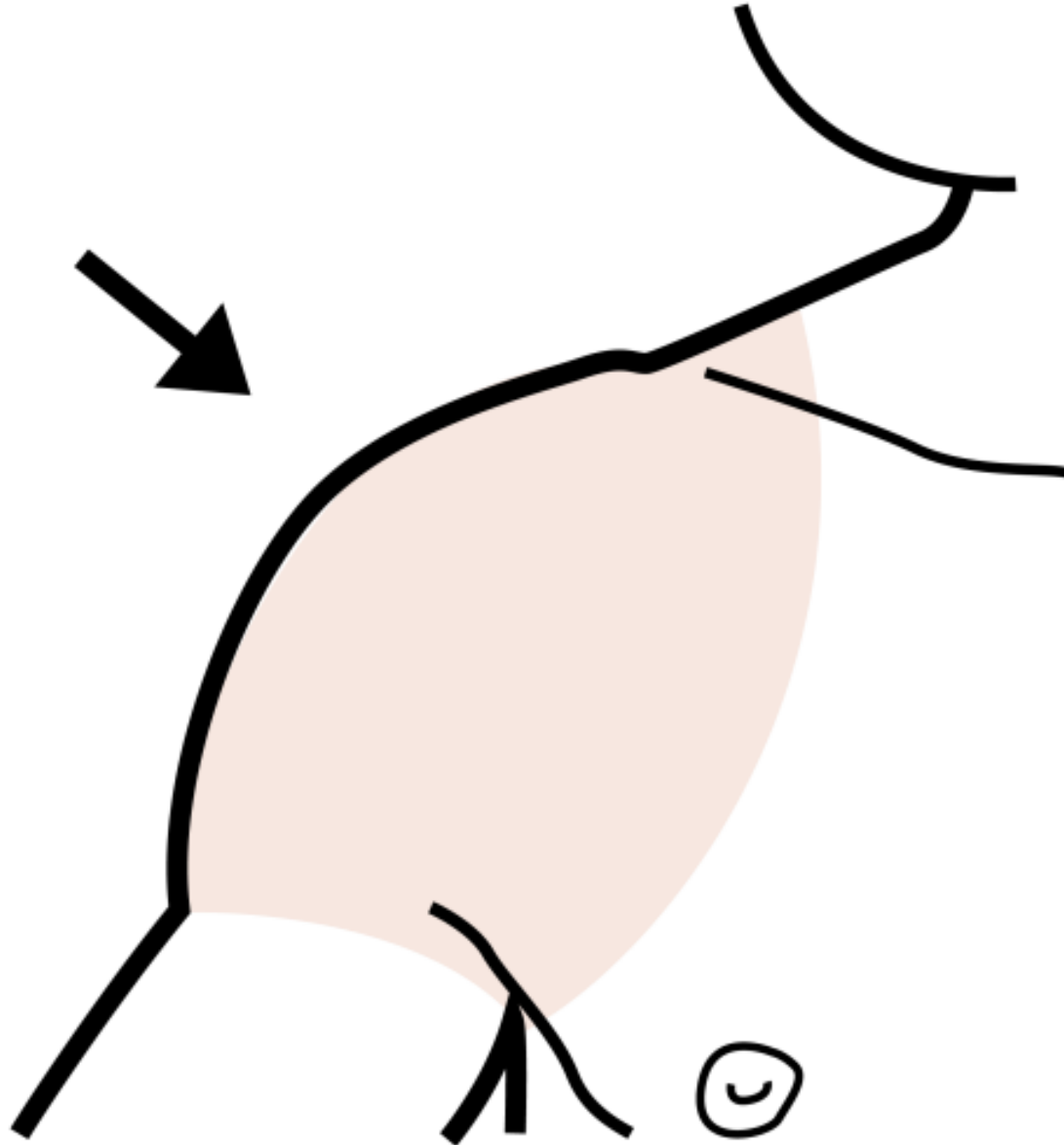
# IL MENTO



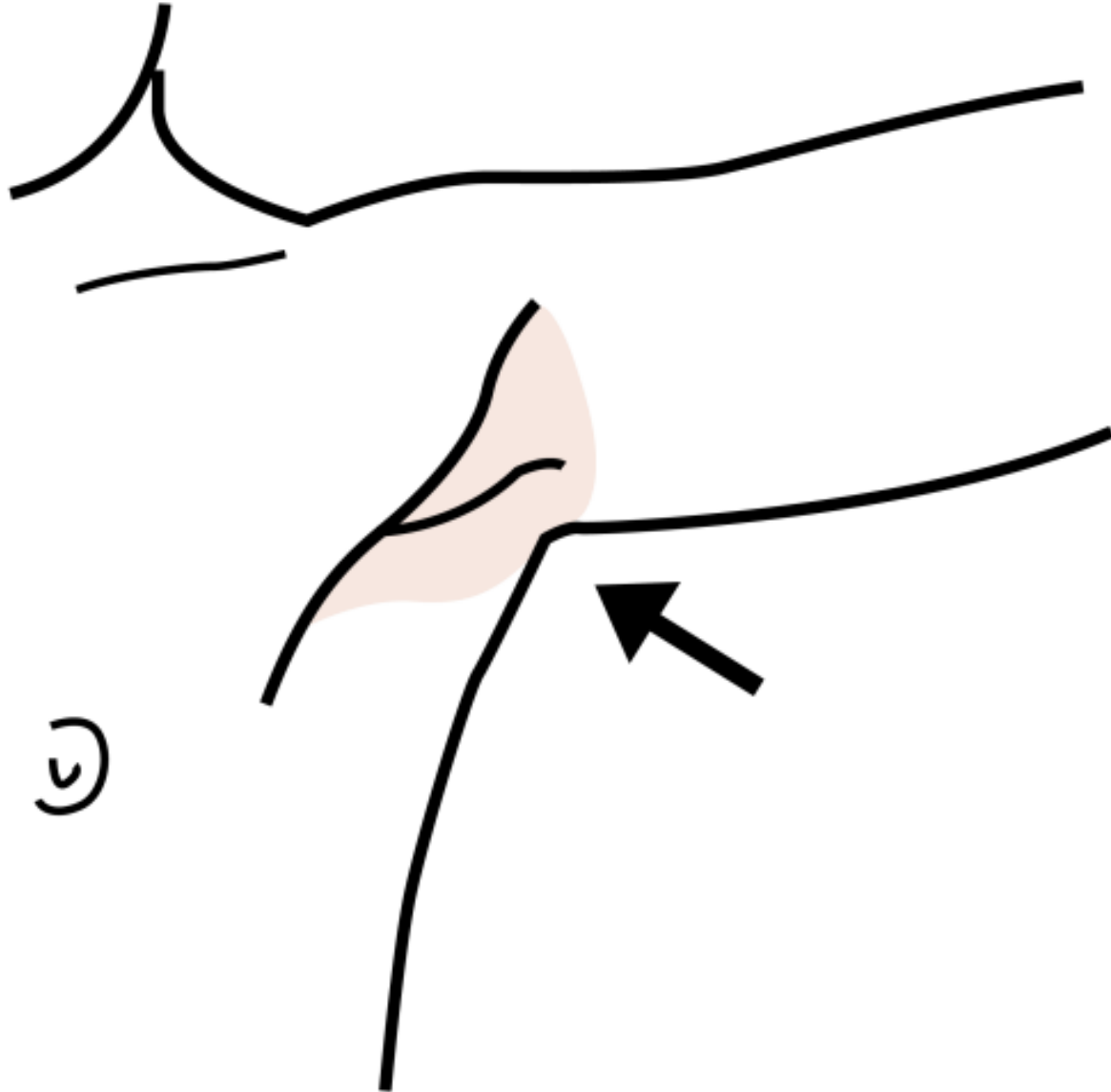
# IL COLLO



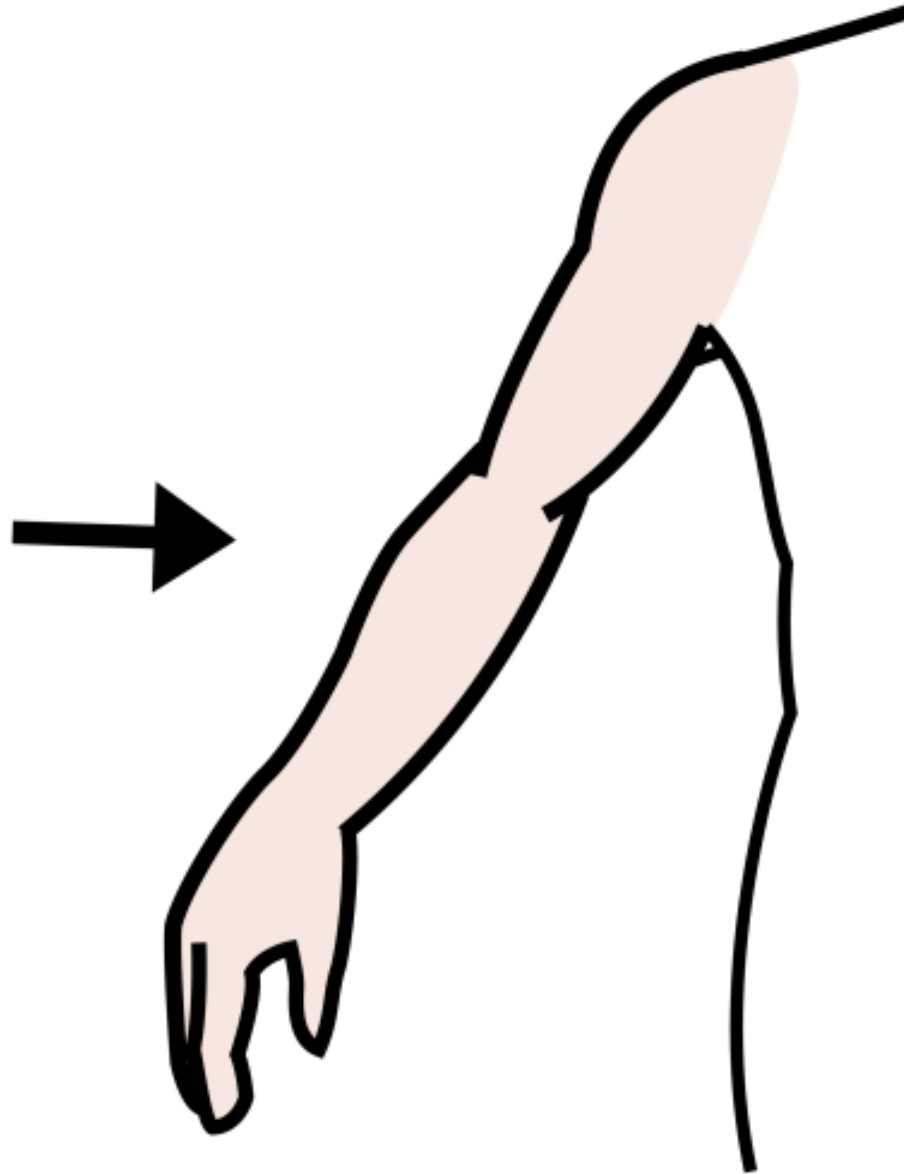
# LA SPALLA



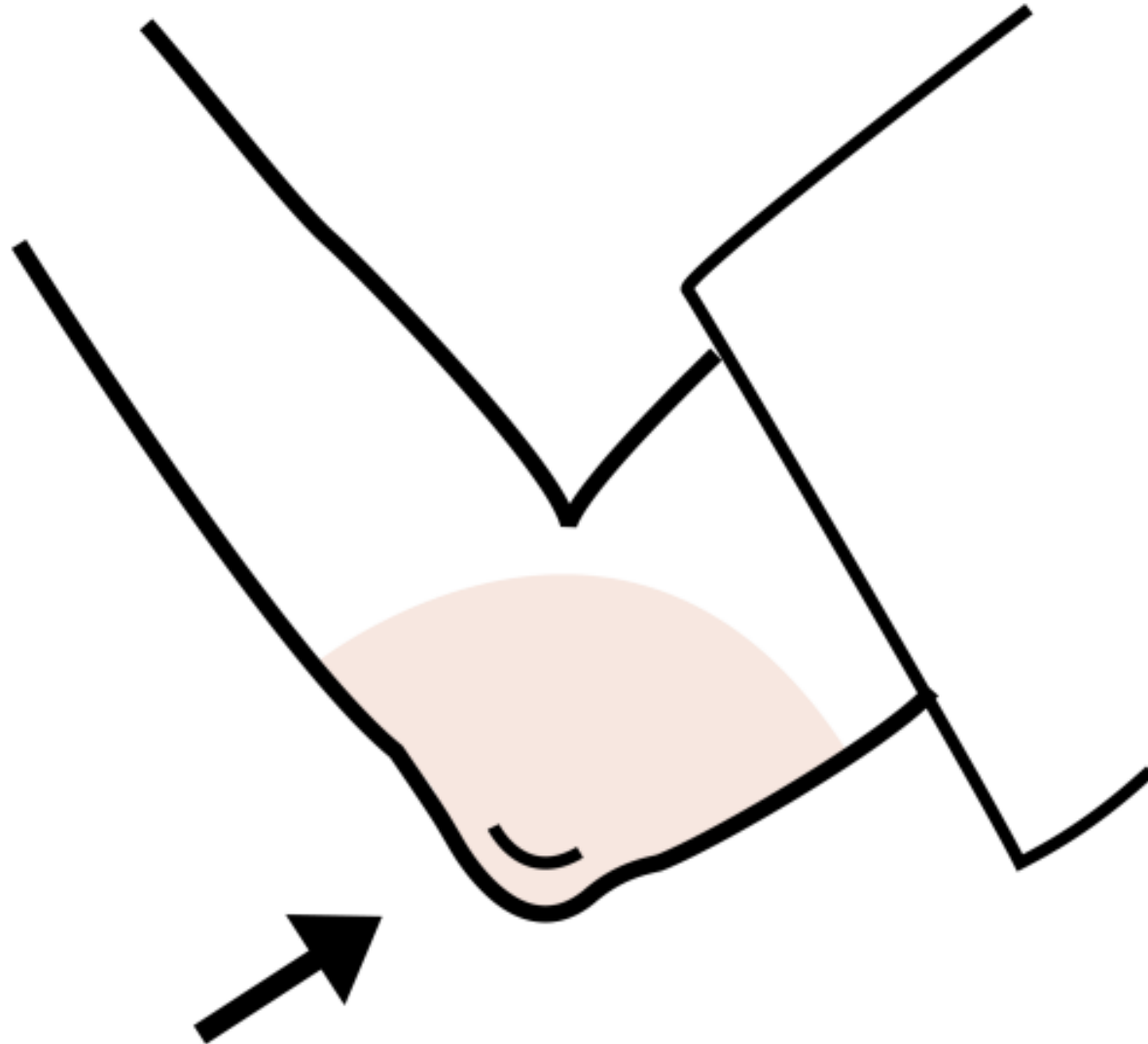
# LA ASCELLA



# IL BRACCIO

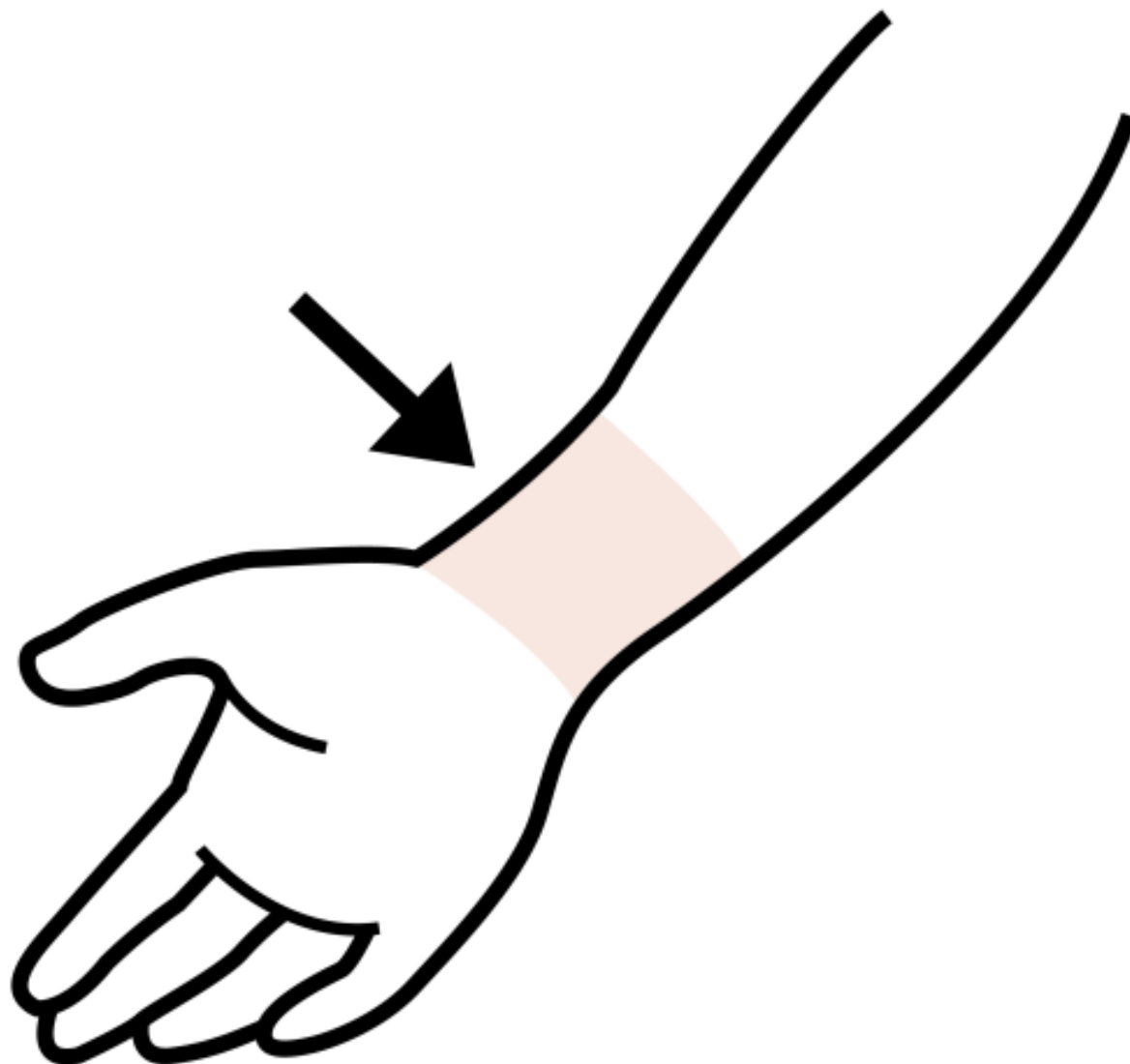


# IL GOMITO

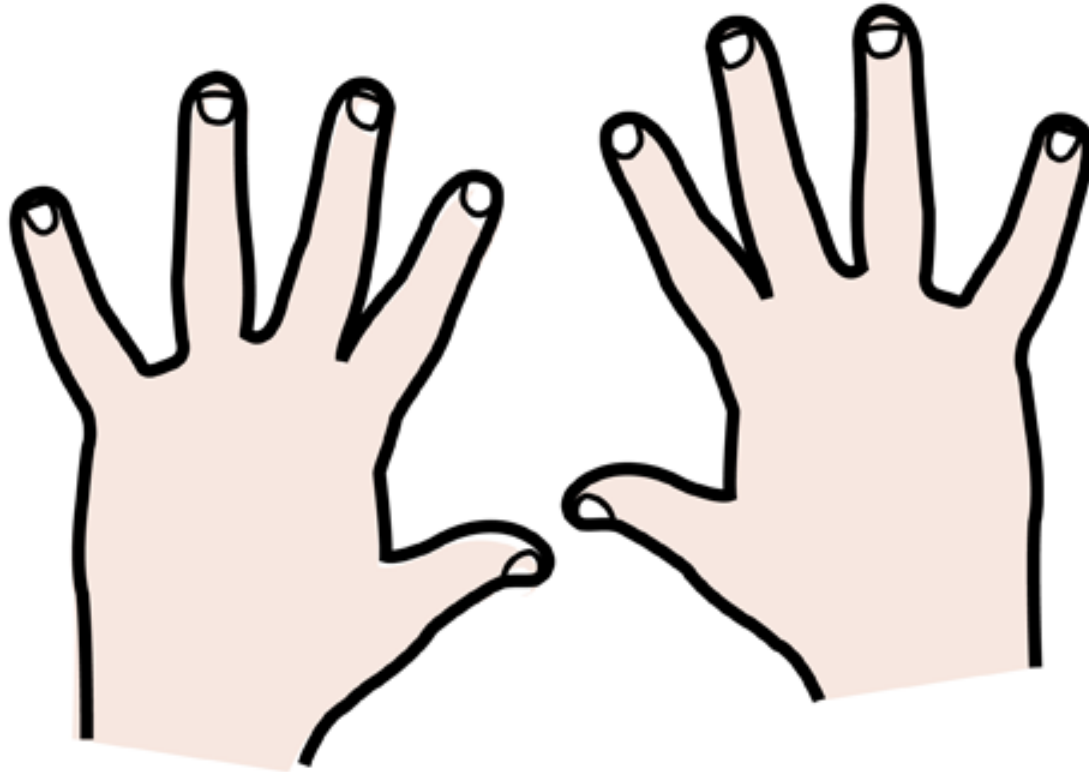




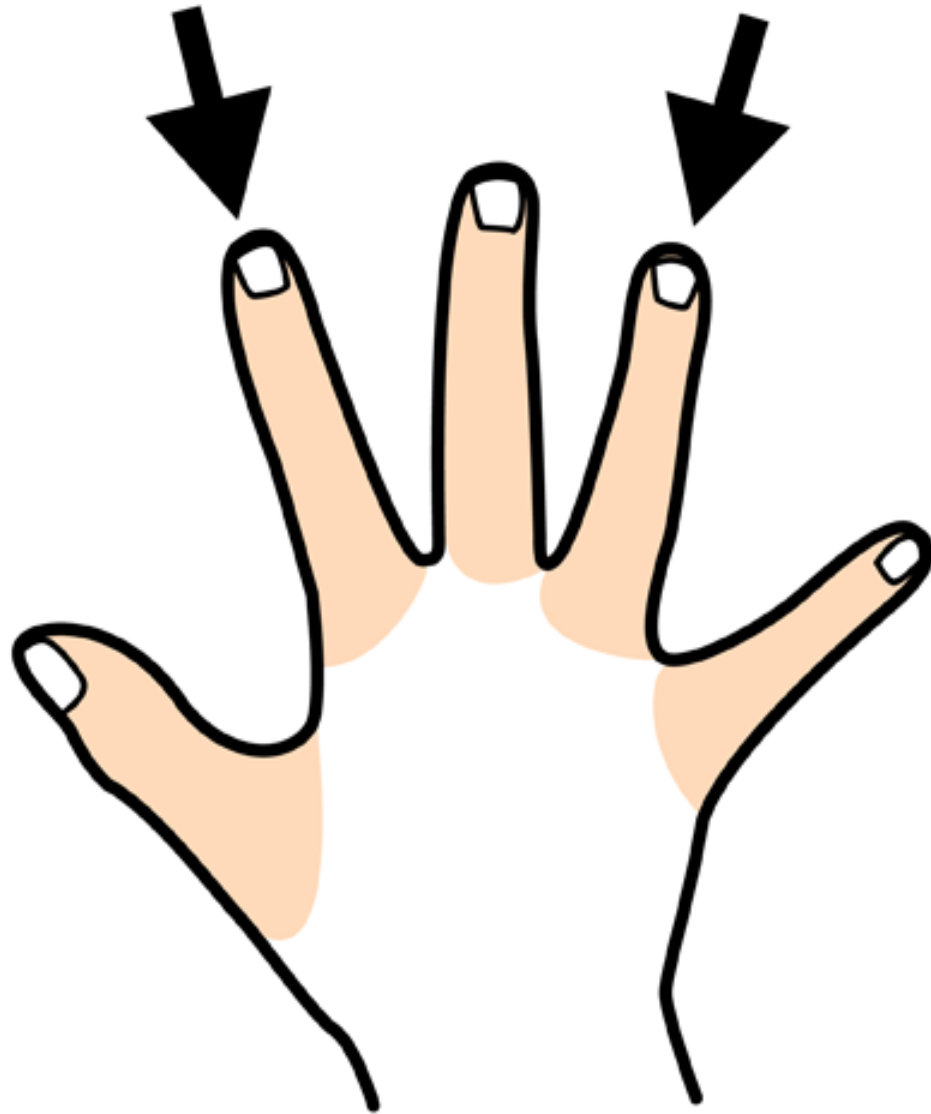
# IL POLSO



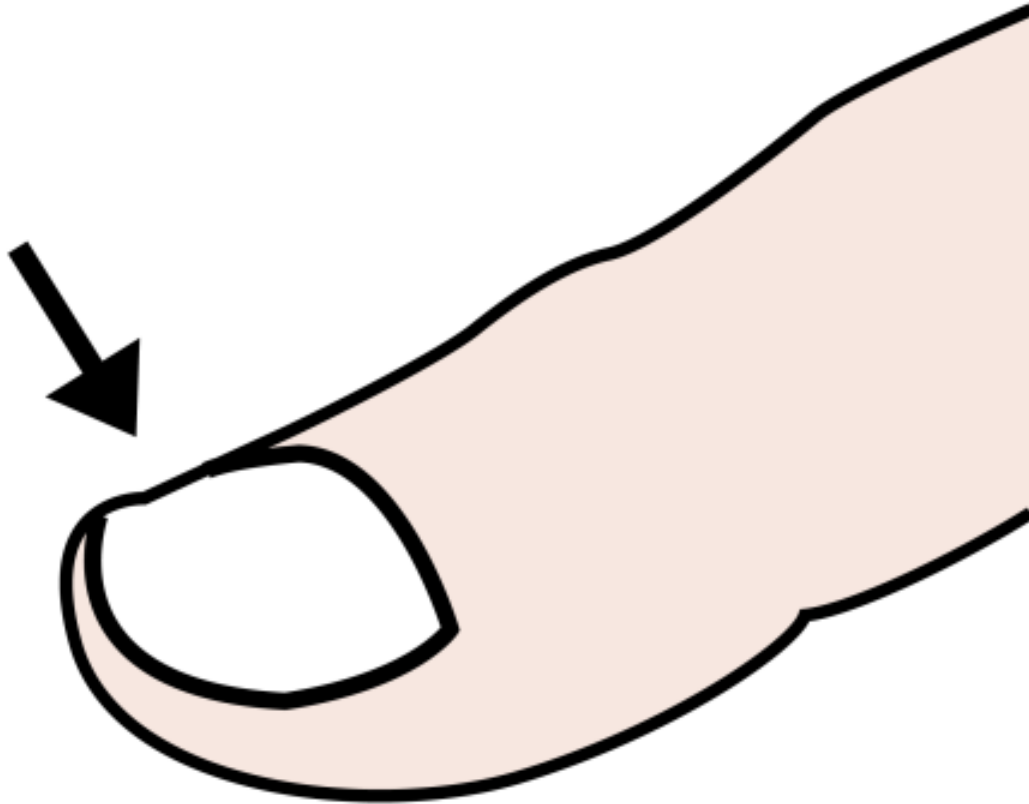
# LE MANI



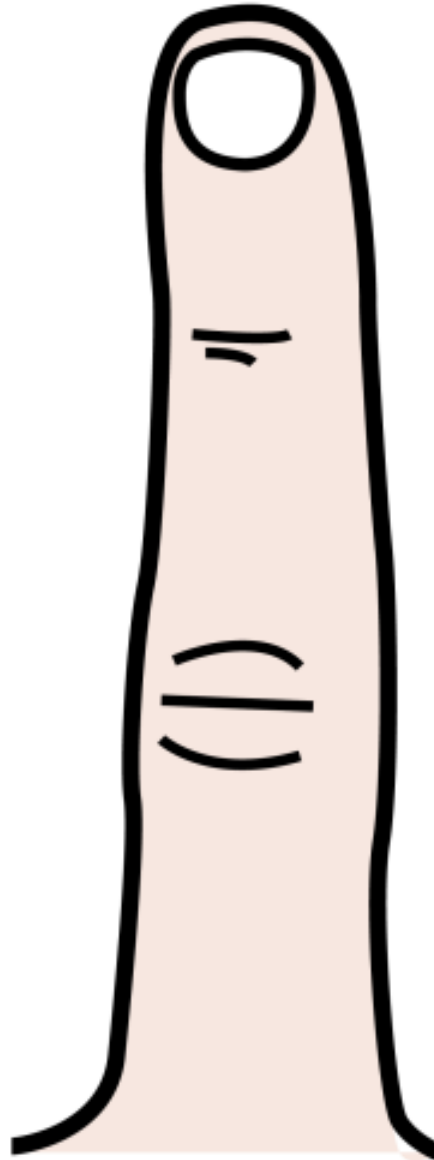
# LE DITA



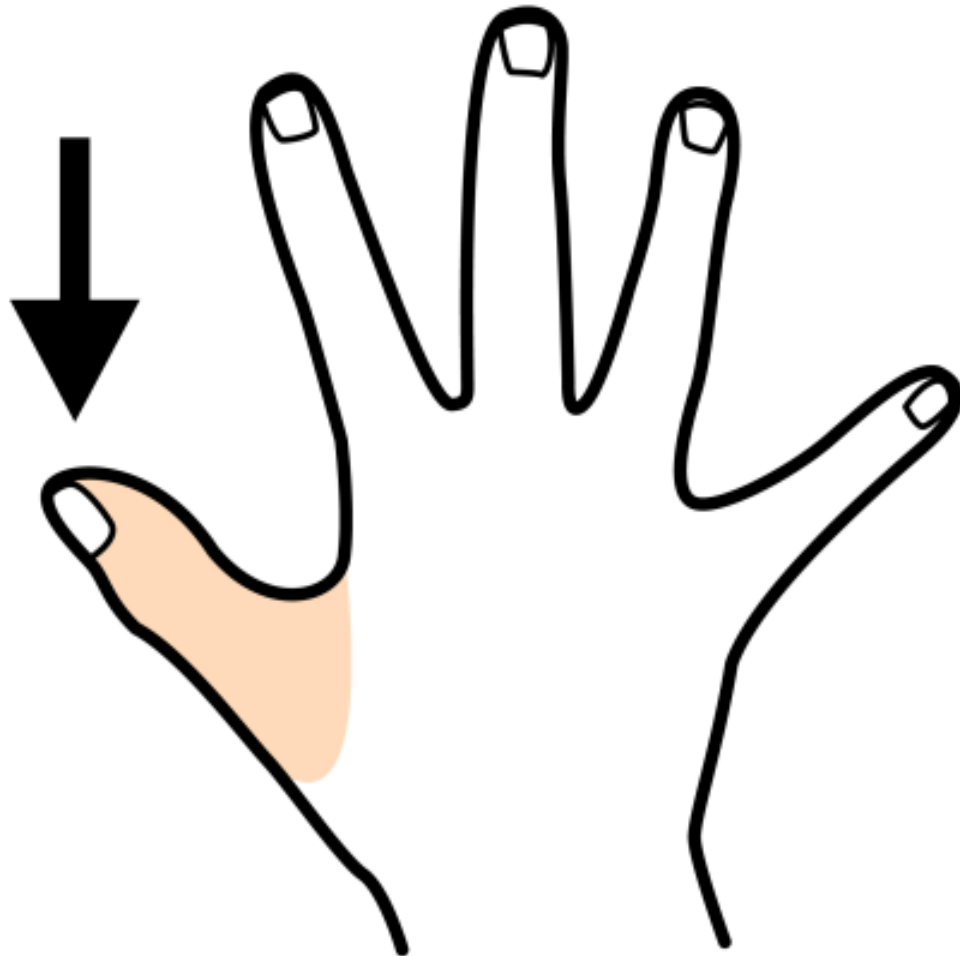
# LA UNGHIA



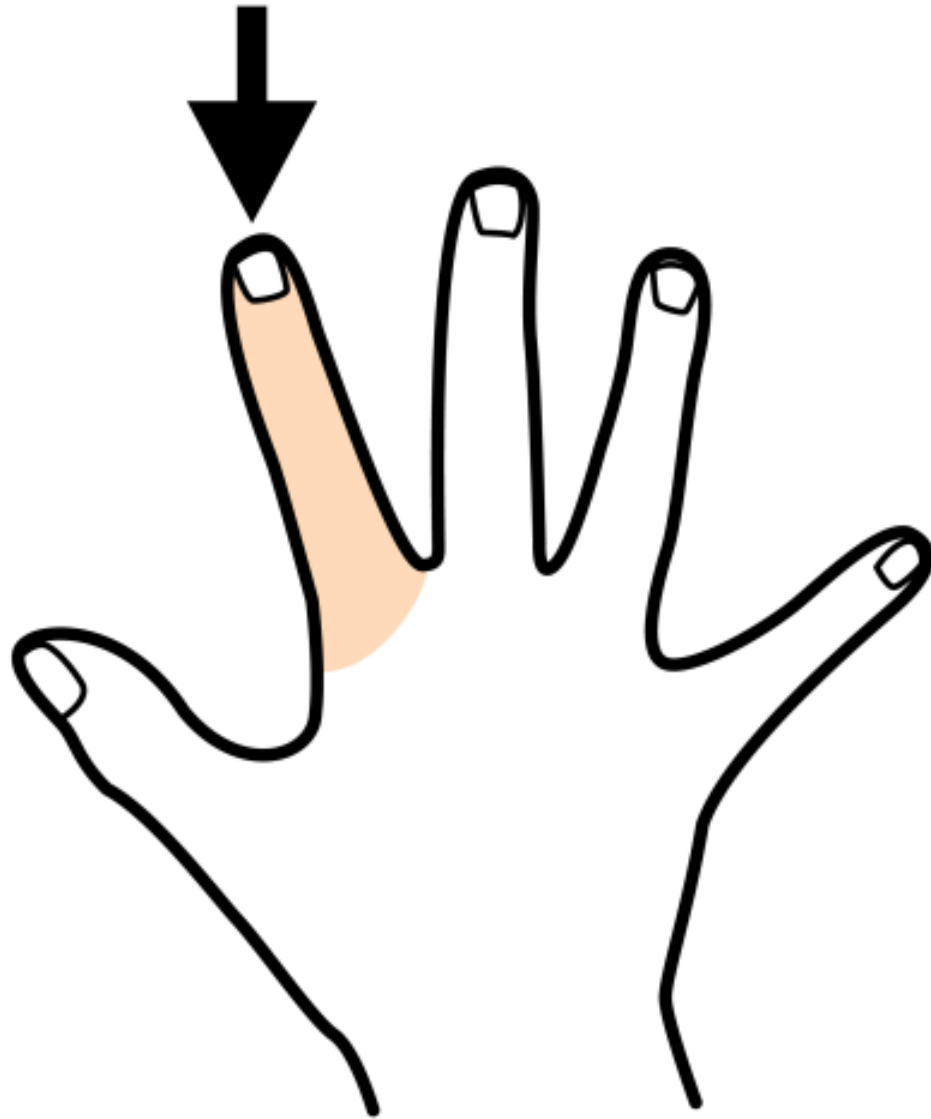
# IL DITO



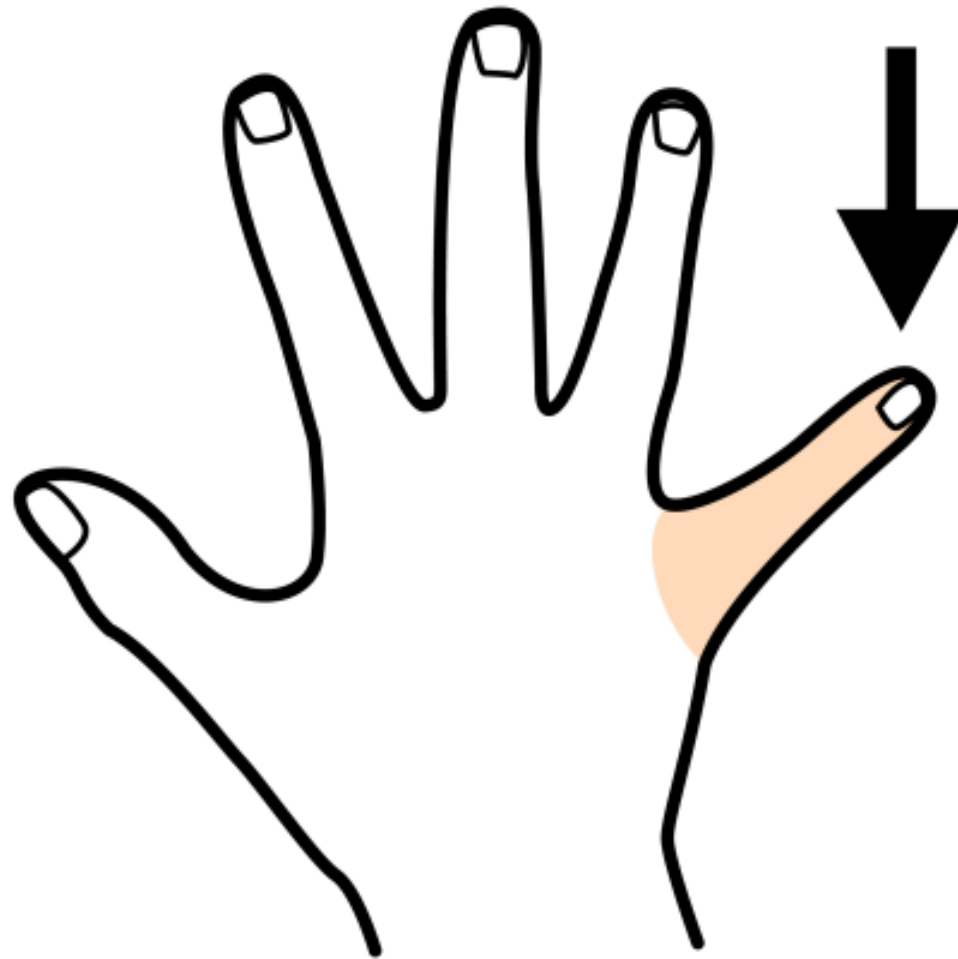
# IL POLLICE



# LO INDICE

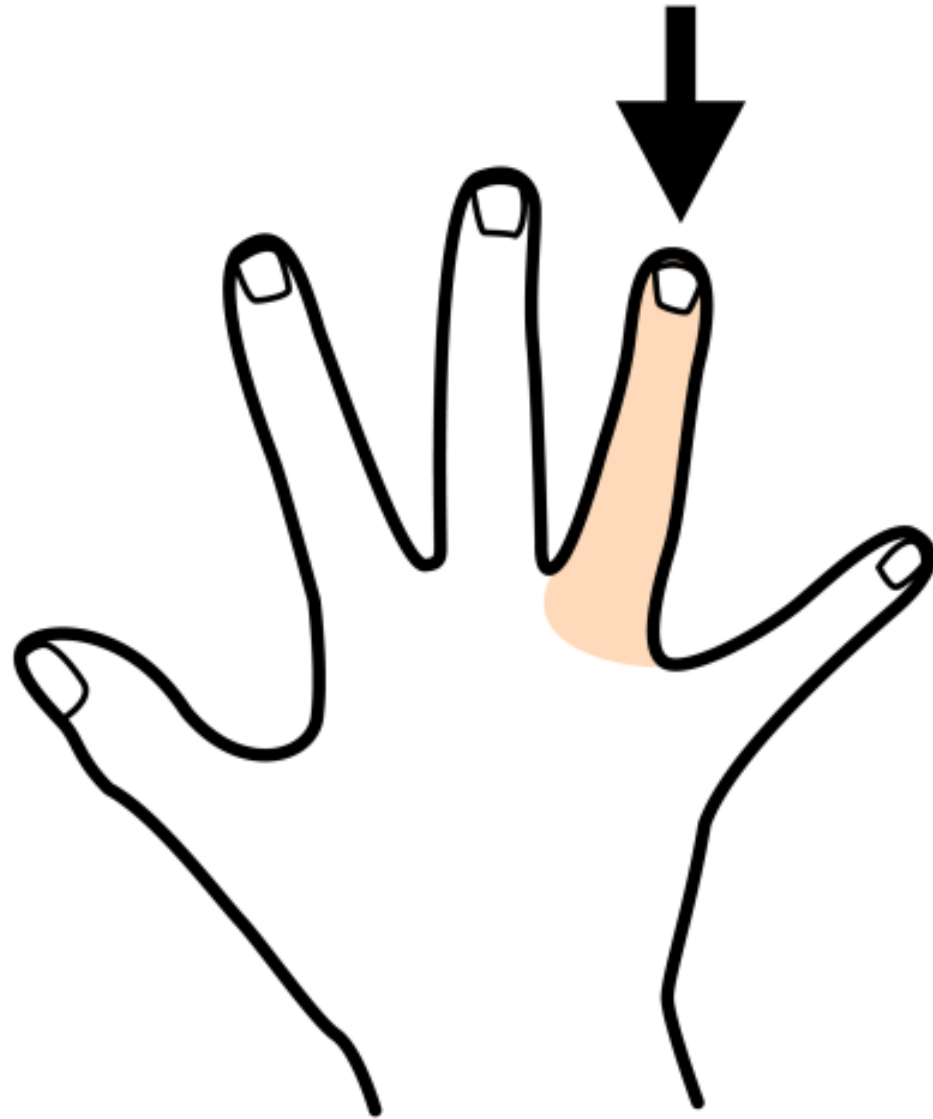


# IL MIGNOLO

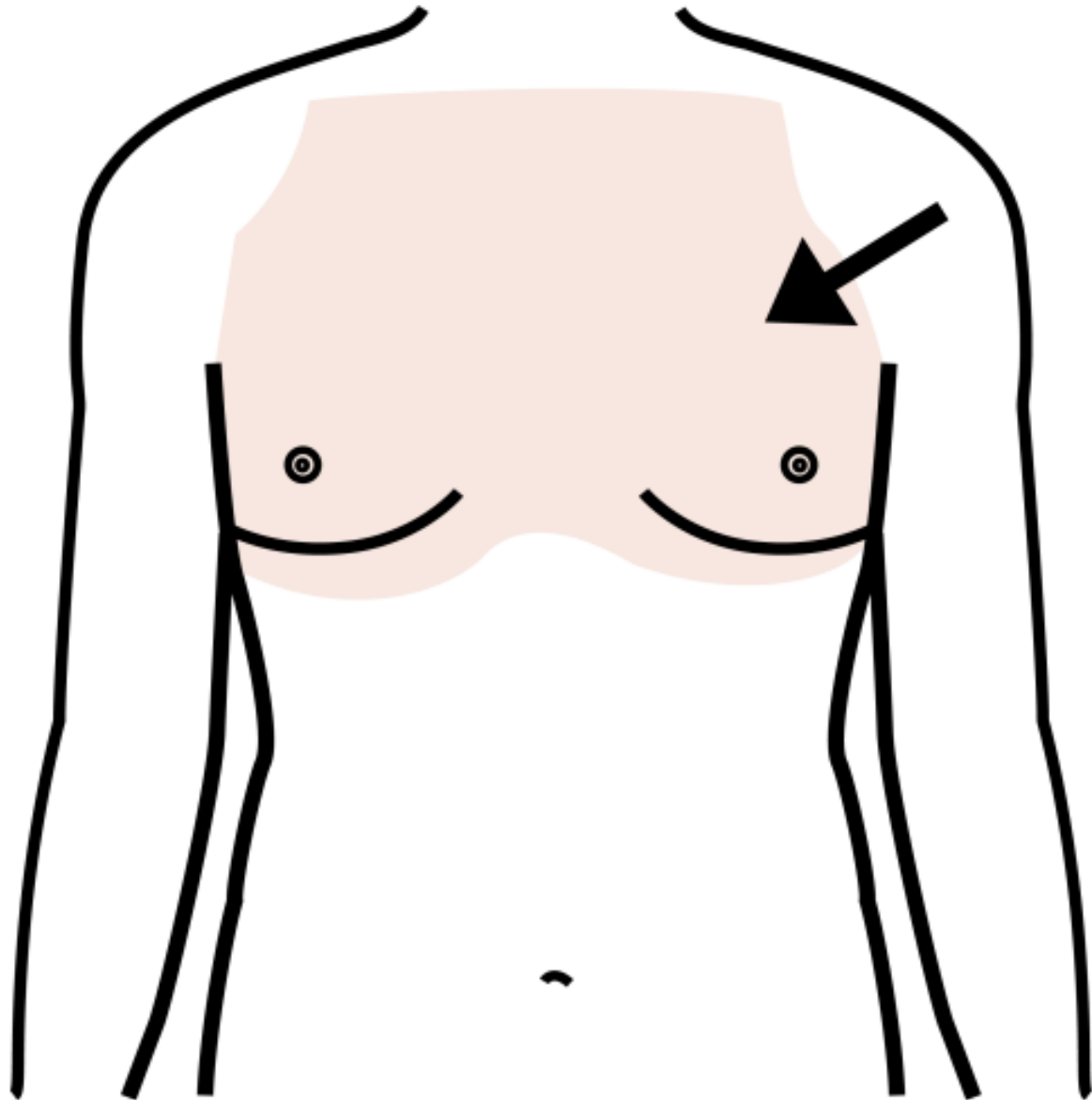




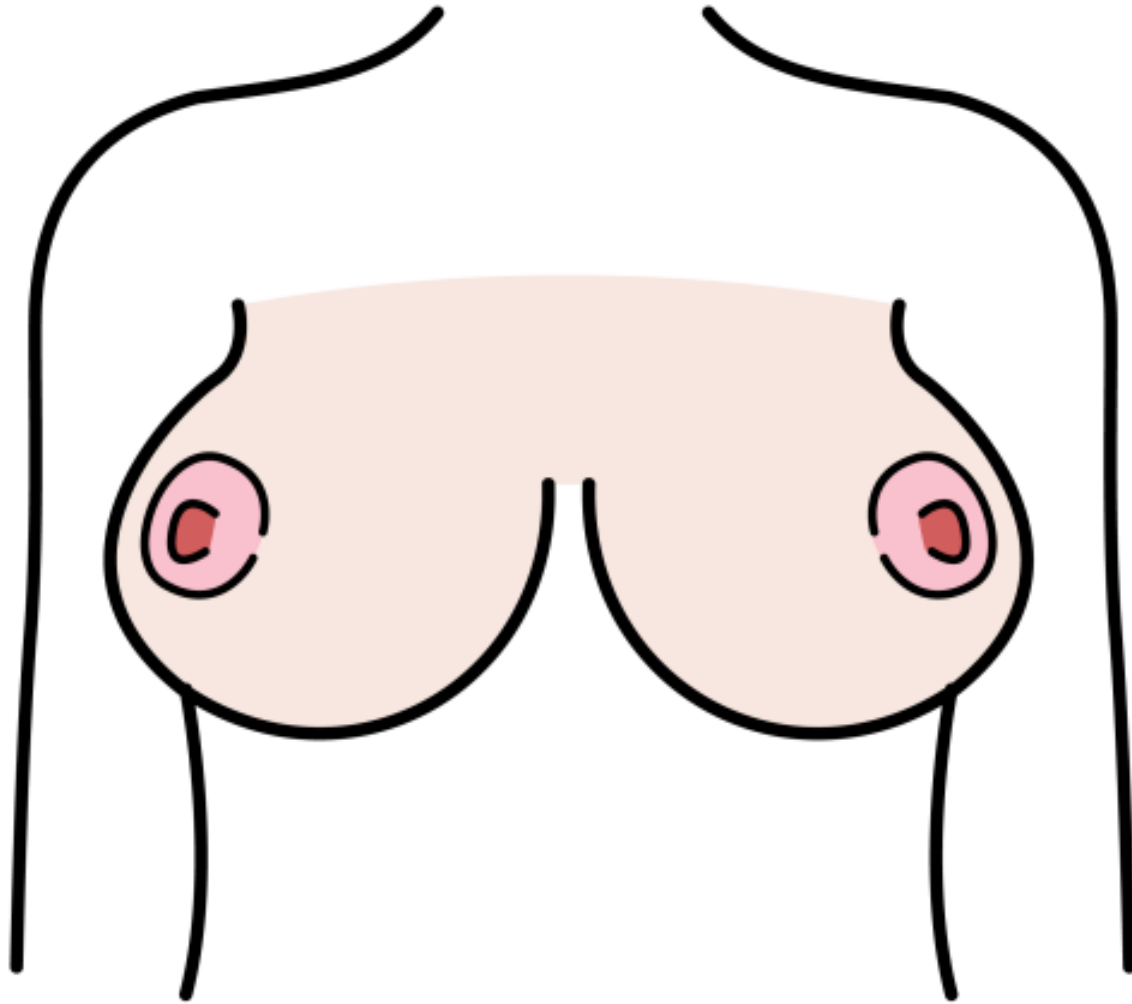
# LO ANULARE



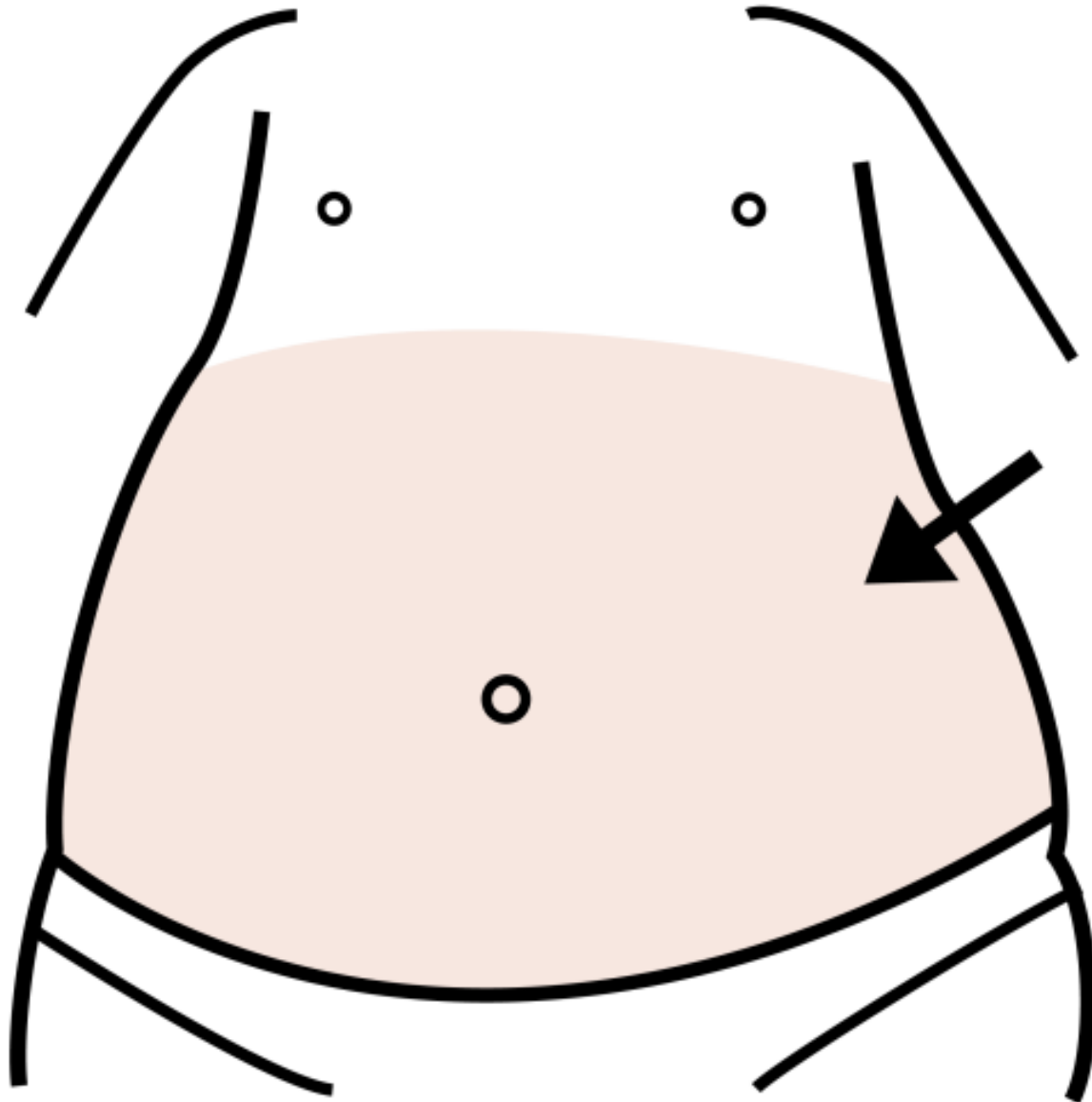
# IL PETTO



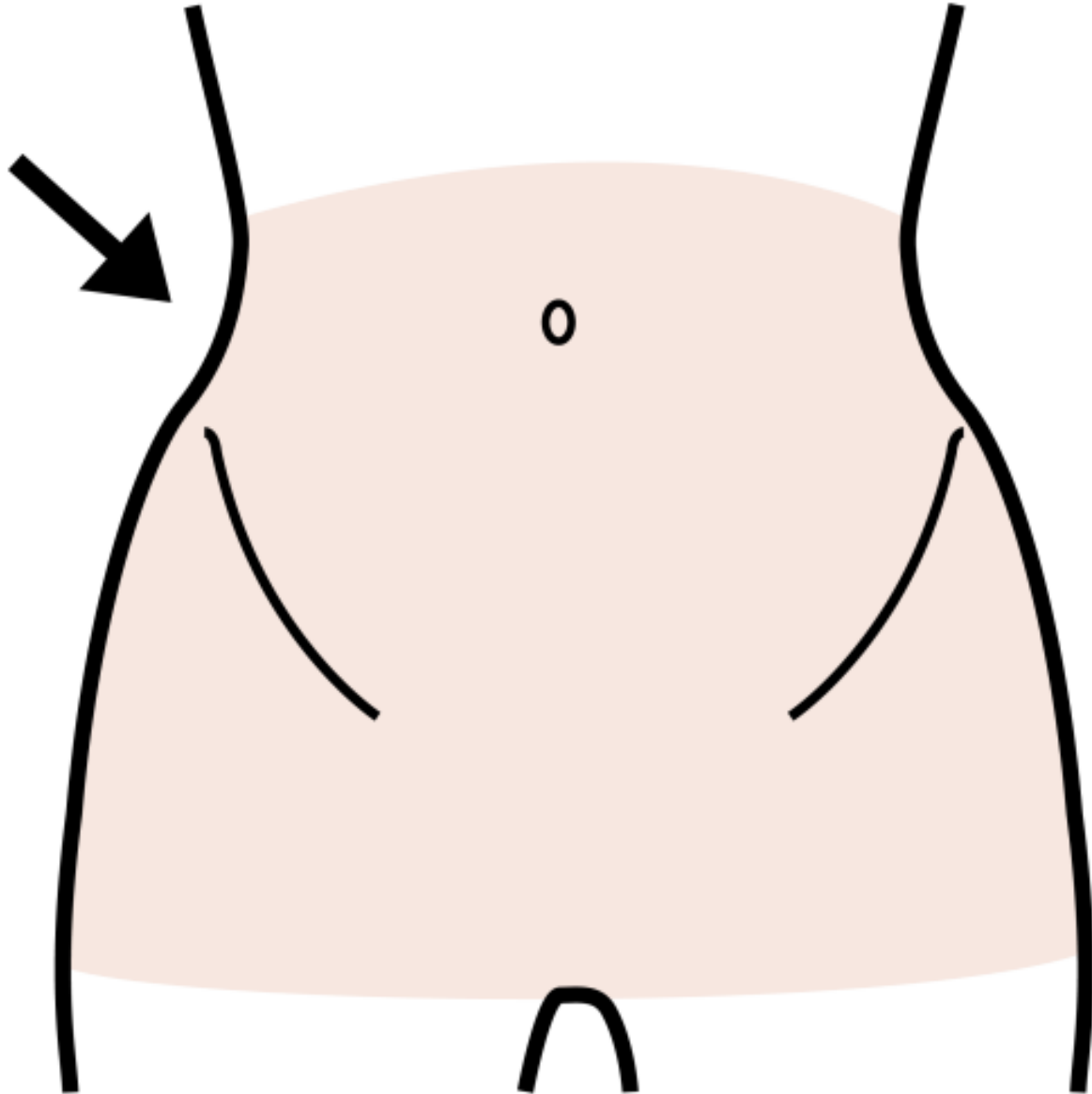
# IL SENO



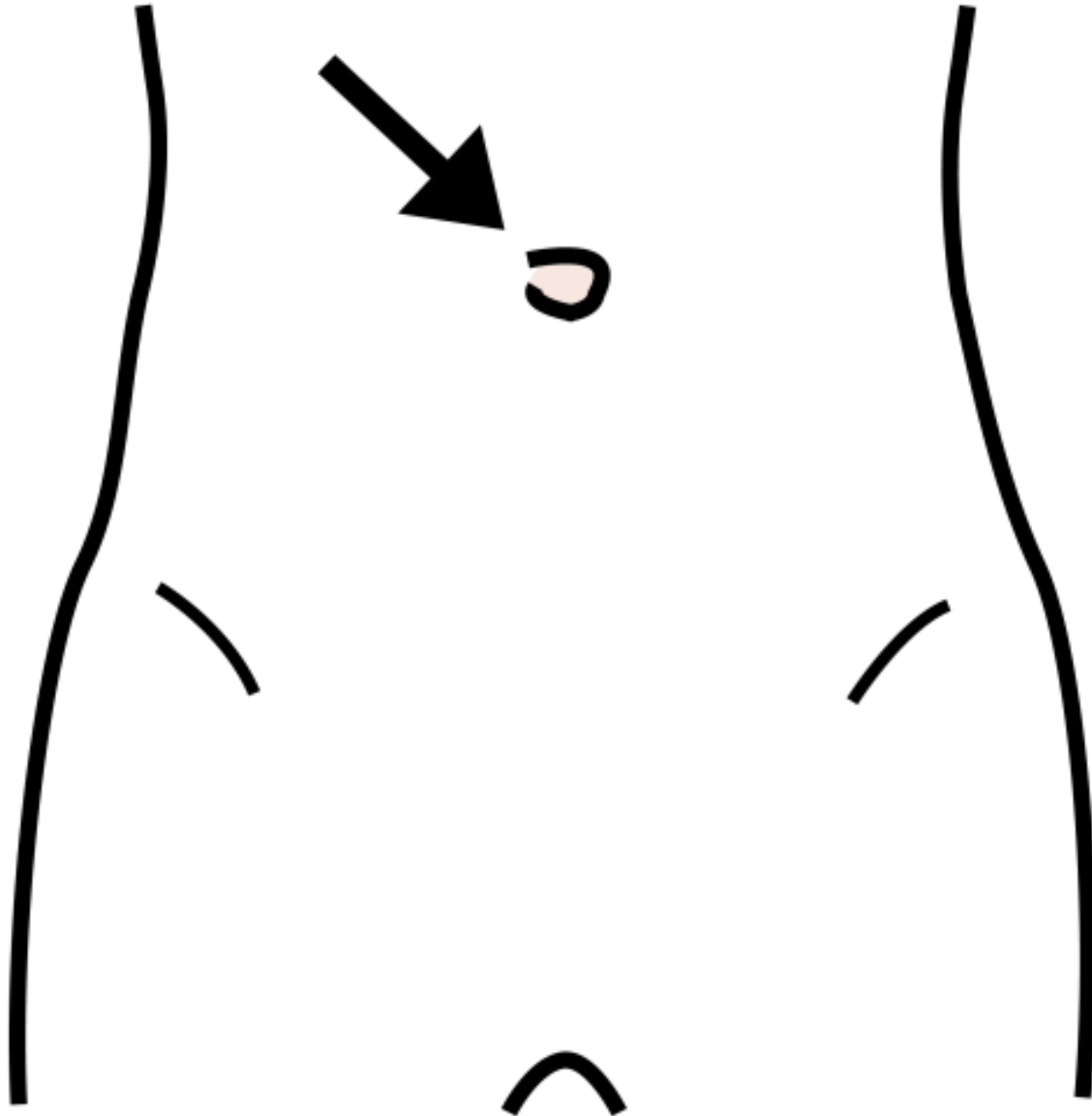
# LA PANCIA



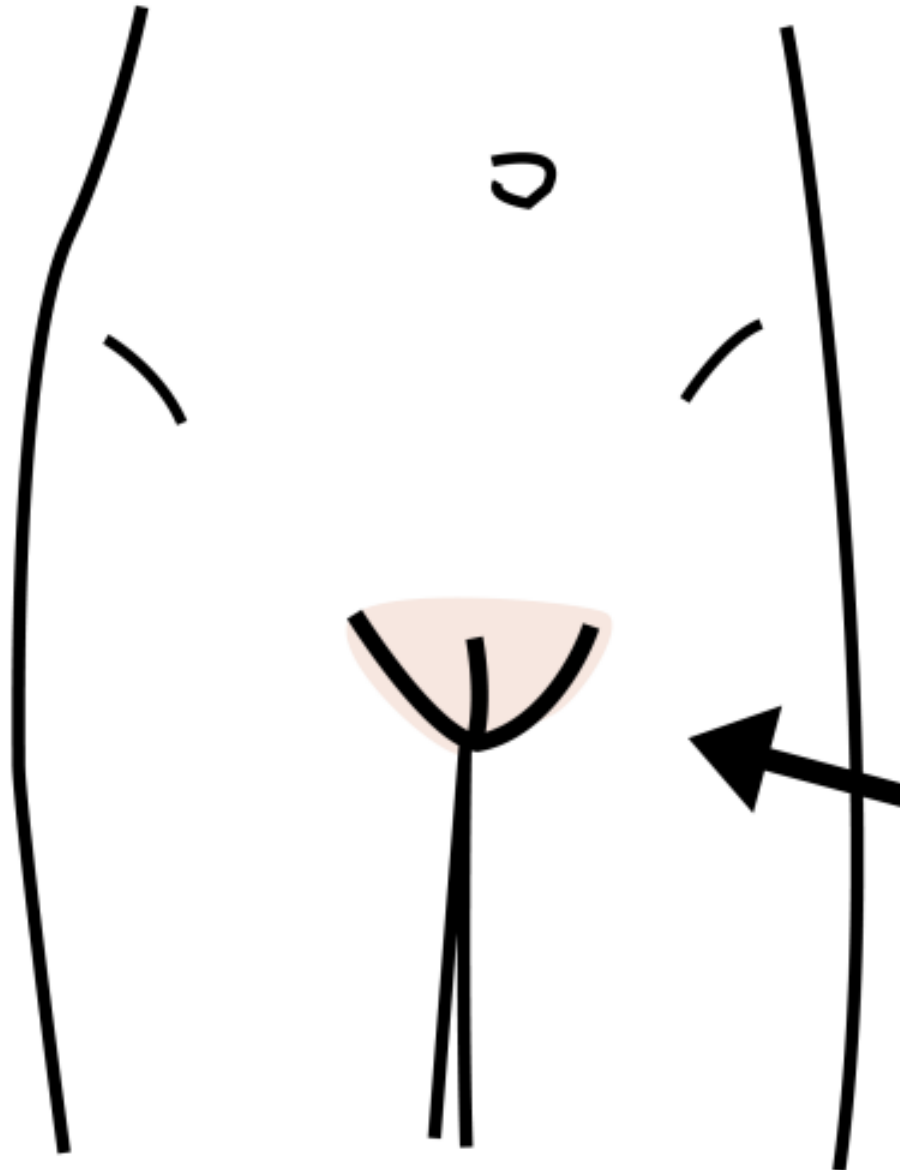
# LE ANCHE



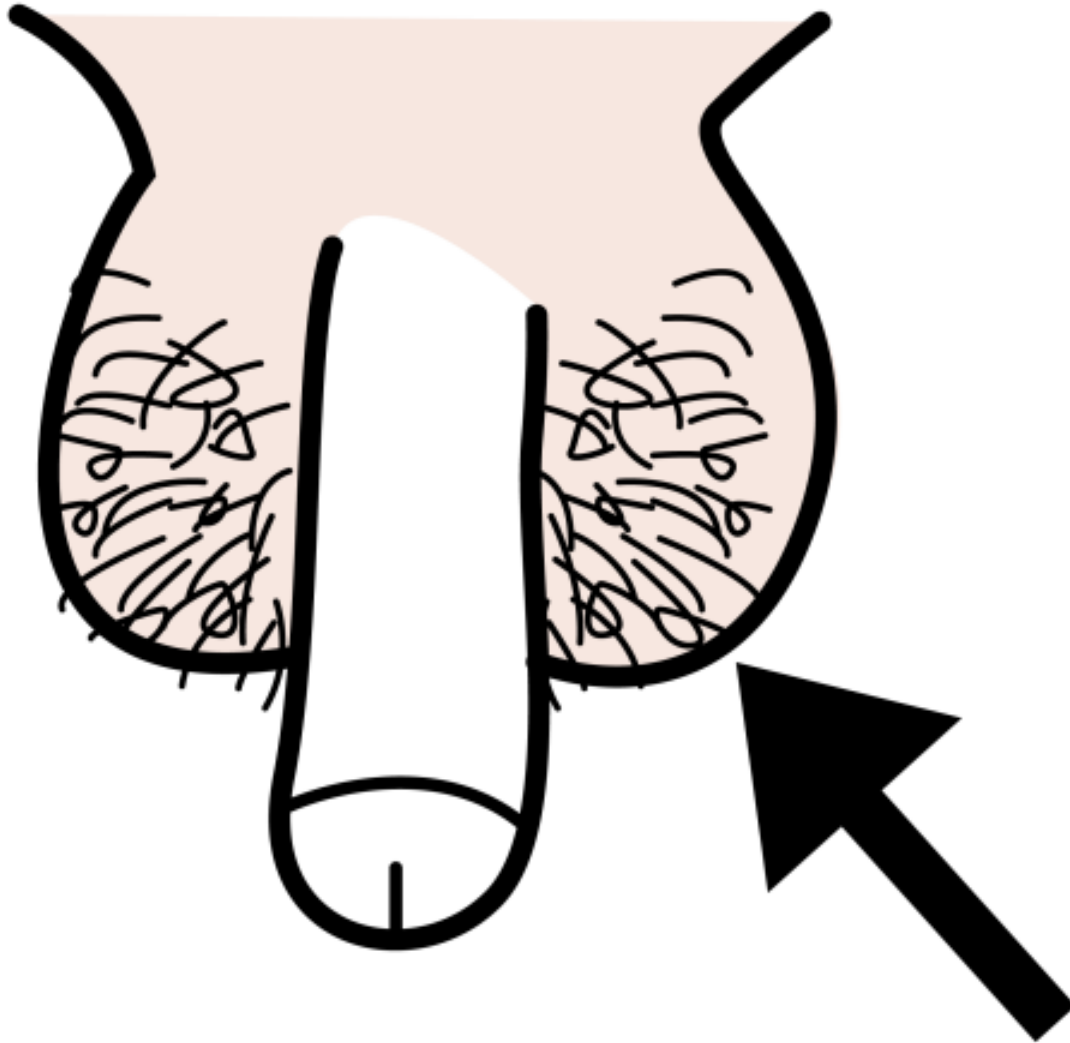
# LO OMBELICO



# LA VULVA

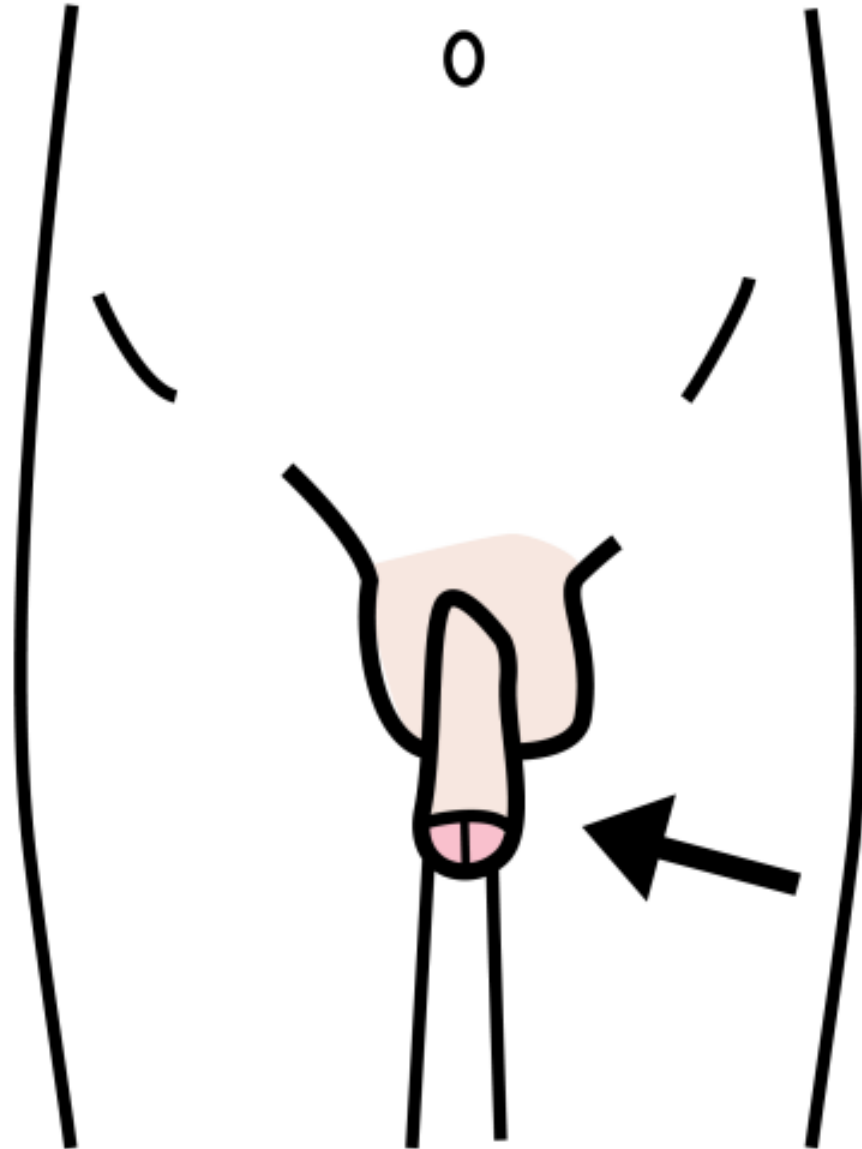


# I TESTICOLI

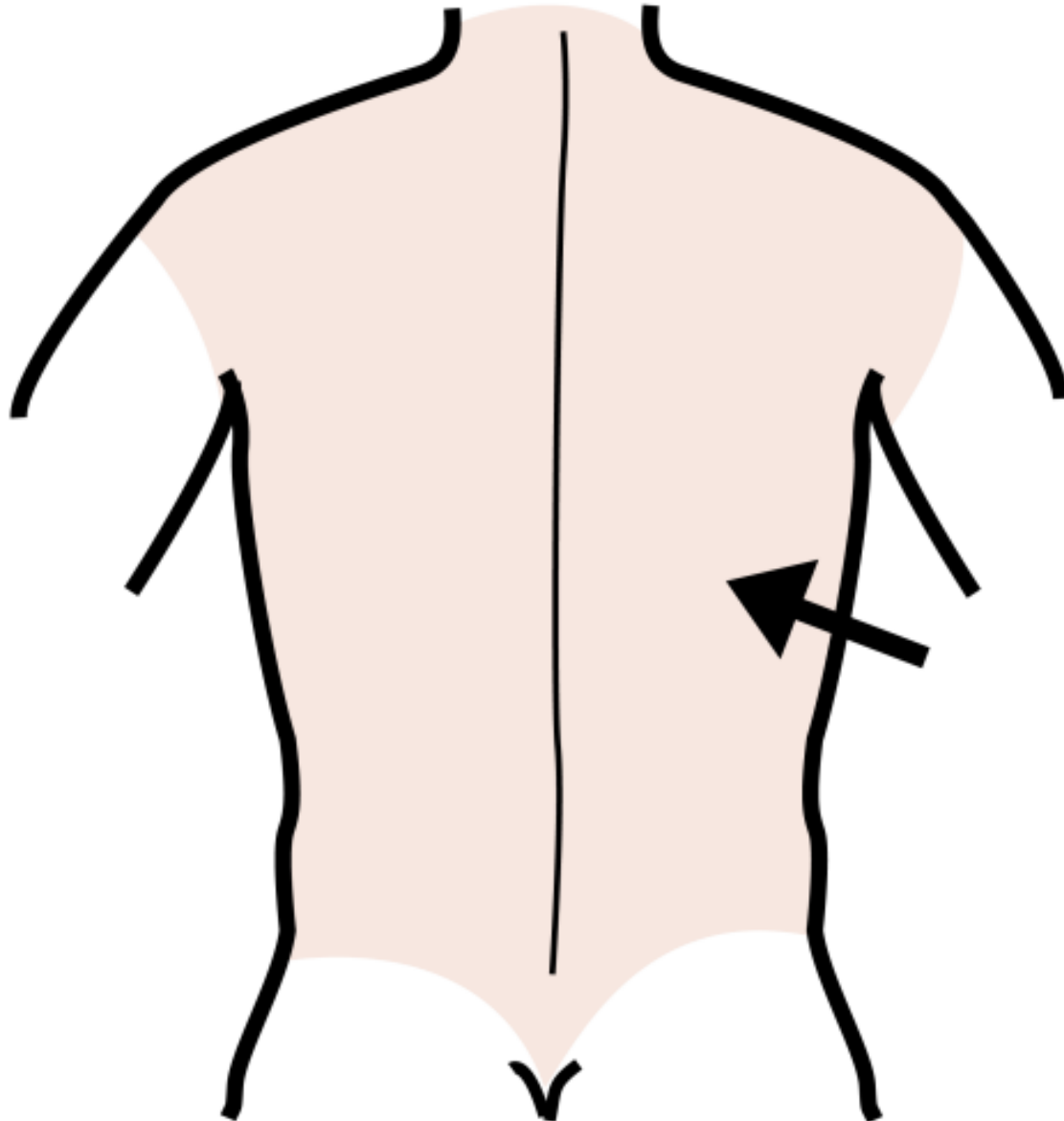




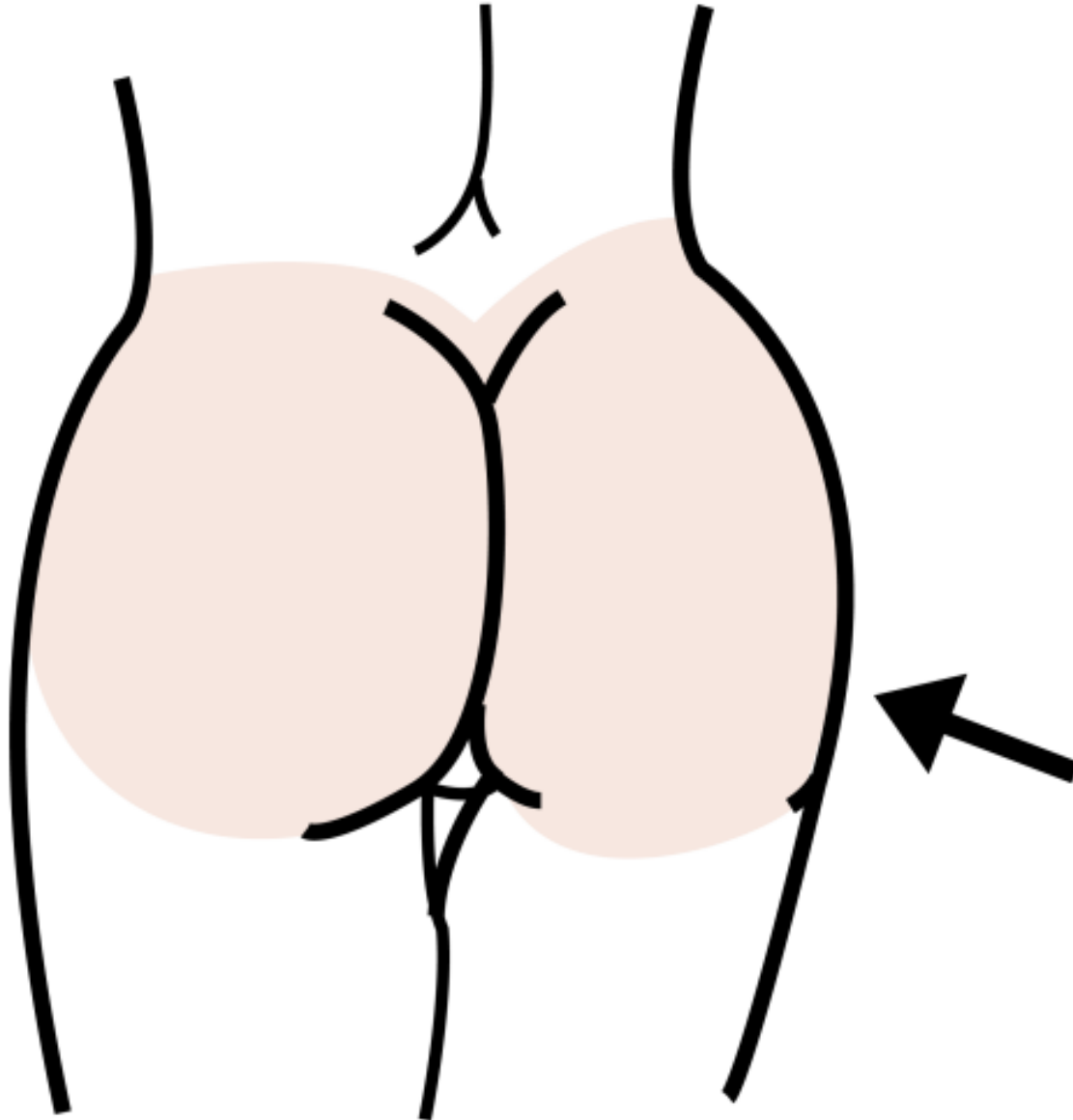
# IL PENE



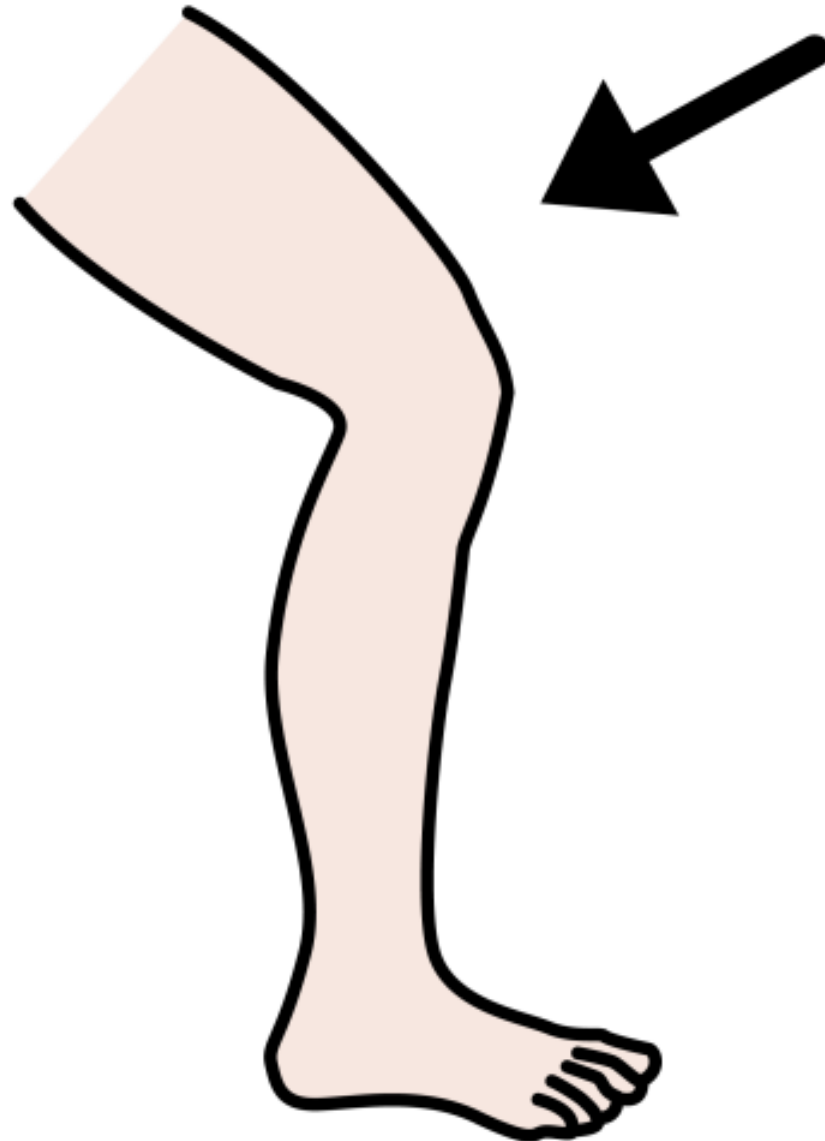
# LA SCHIENA



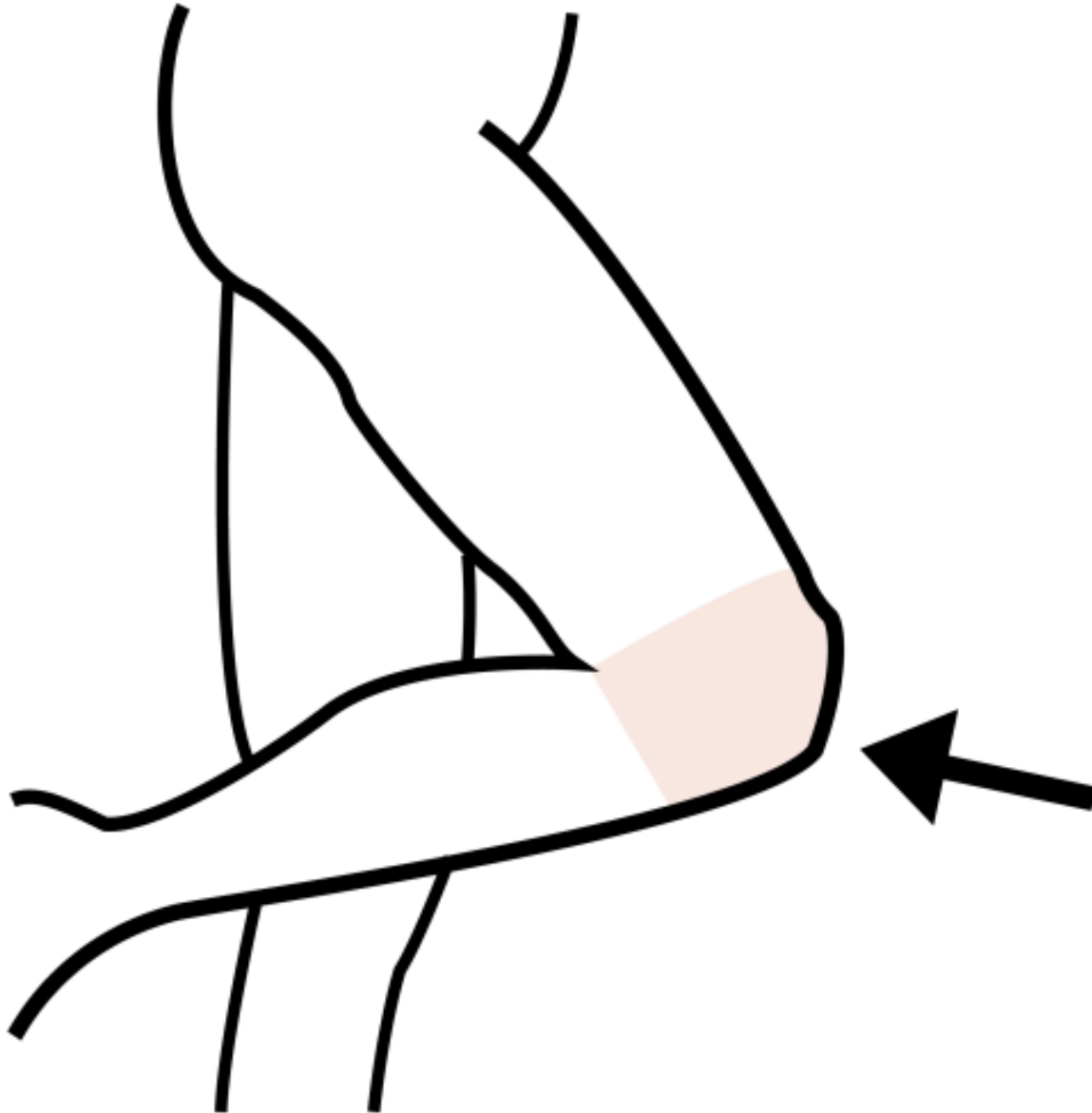
# IL SEDERE



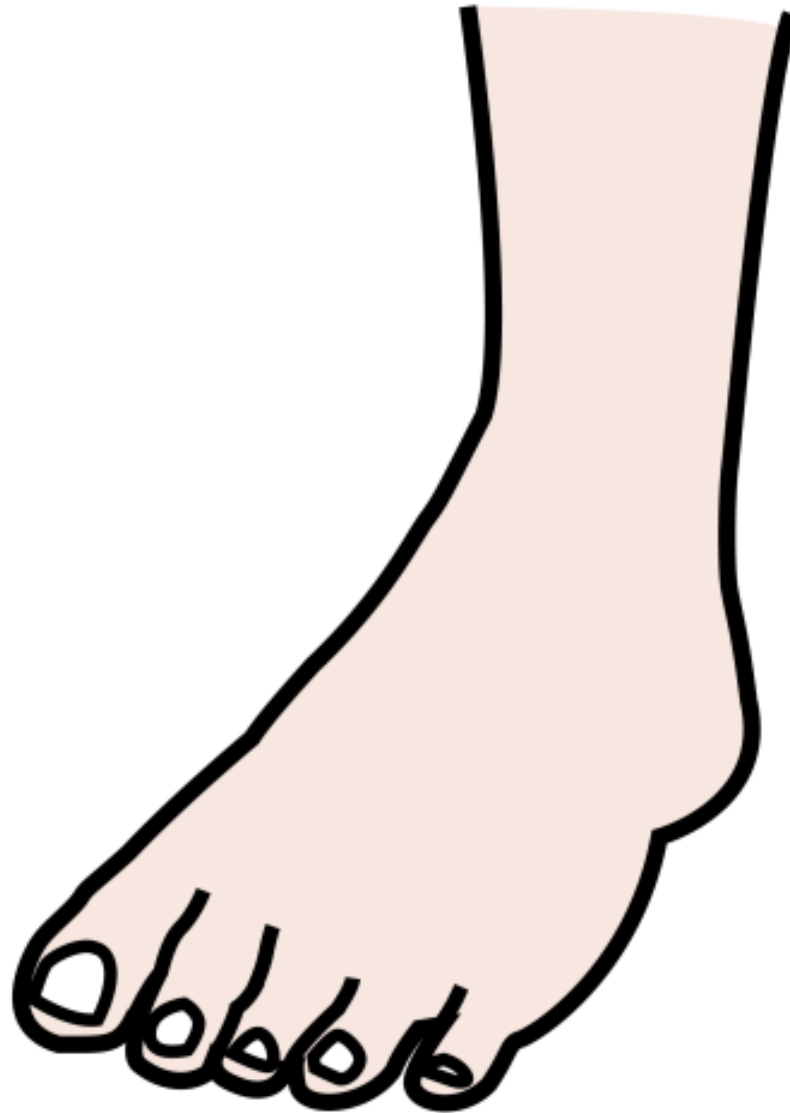# LA GAMBA



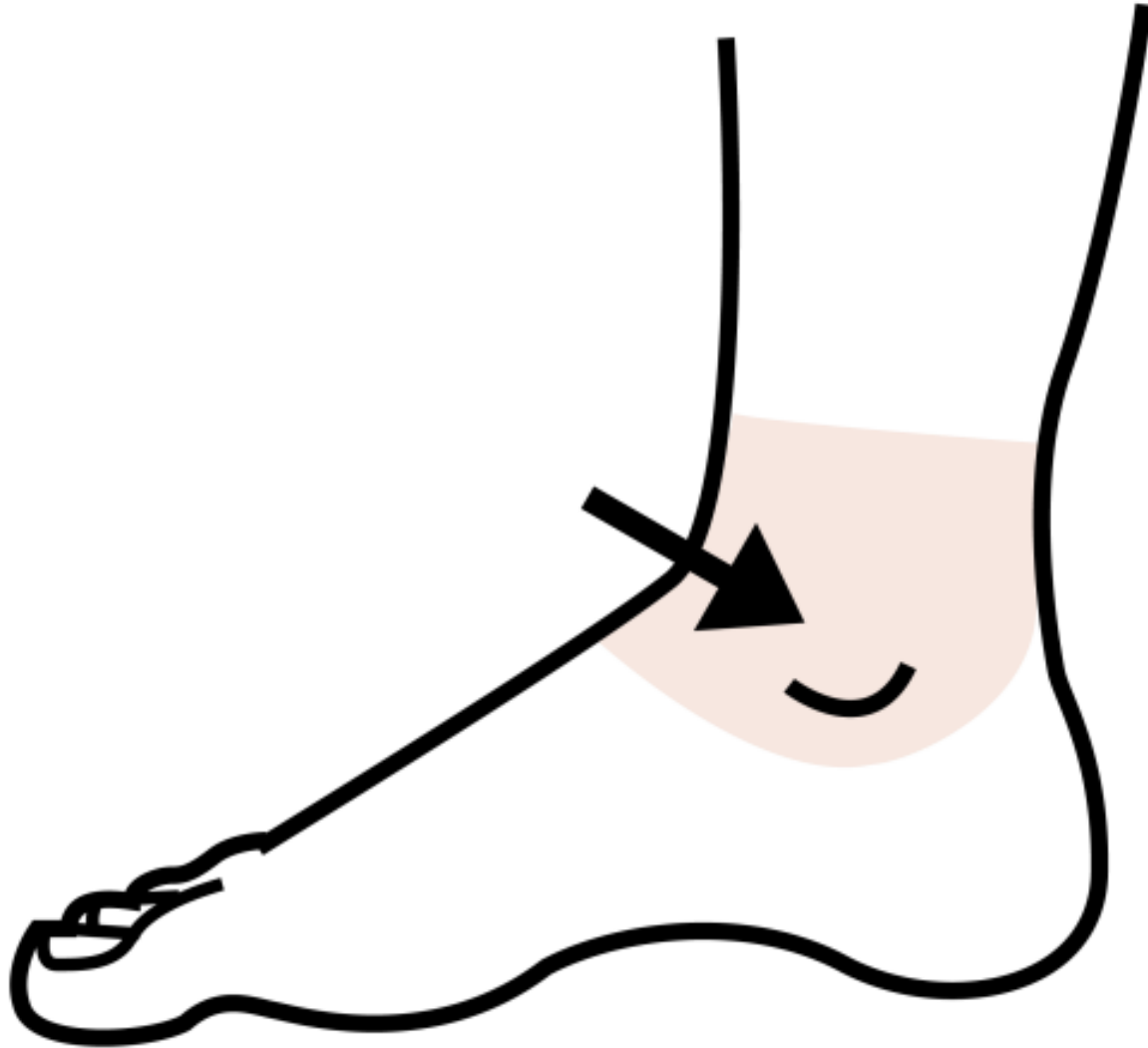
# IL GINOCCHIO



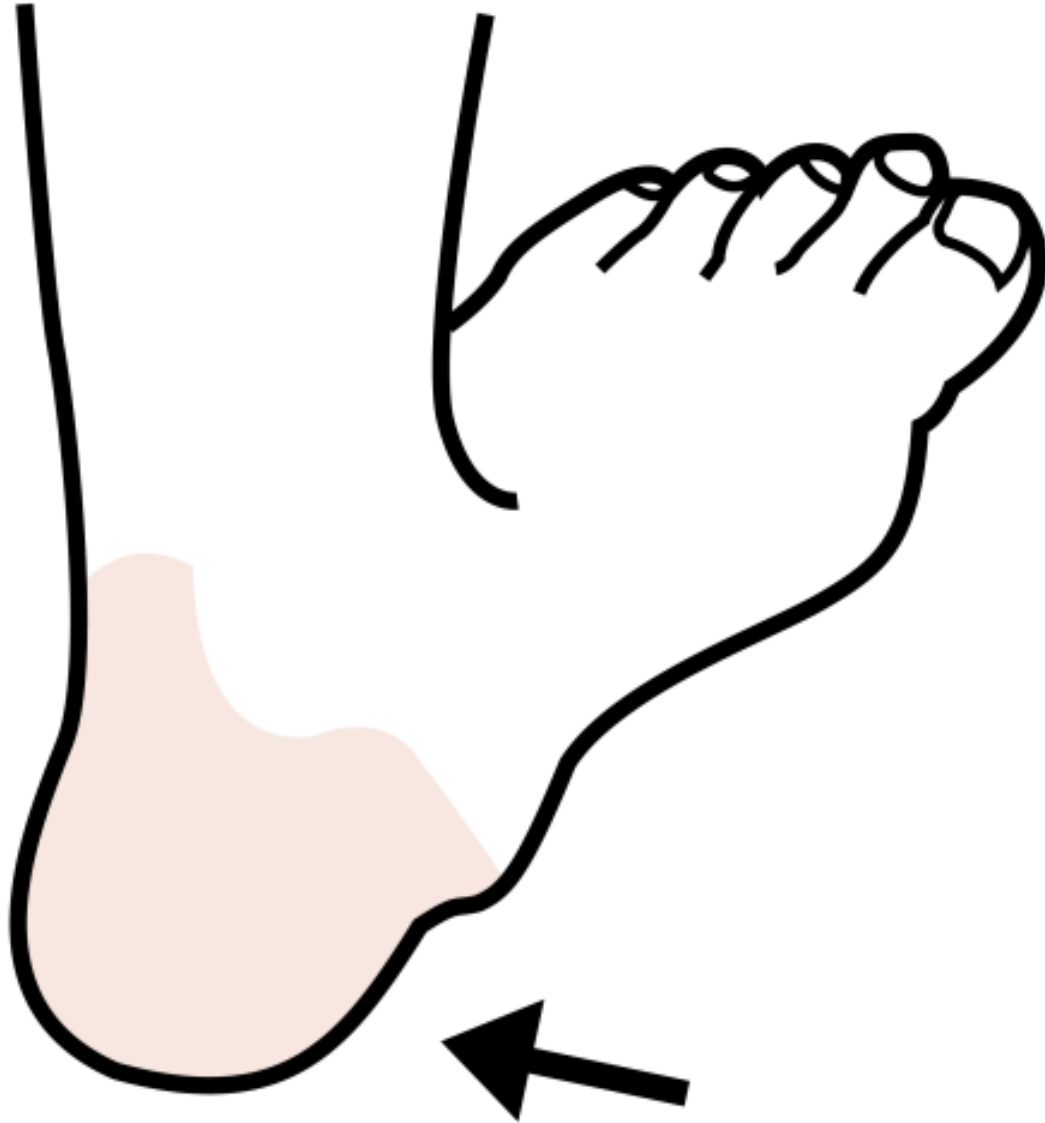# IL PIEDE



# LA CAVIGLIA

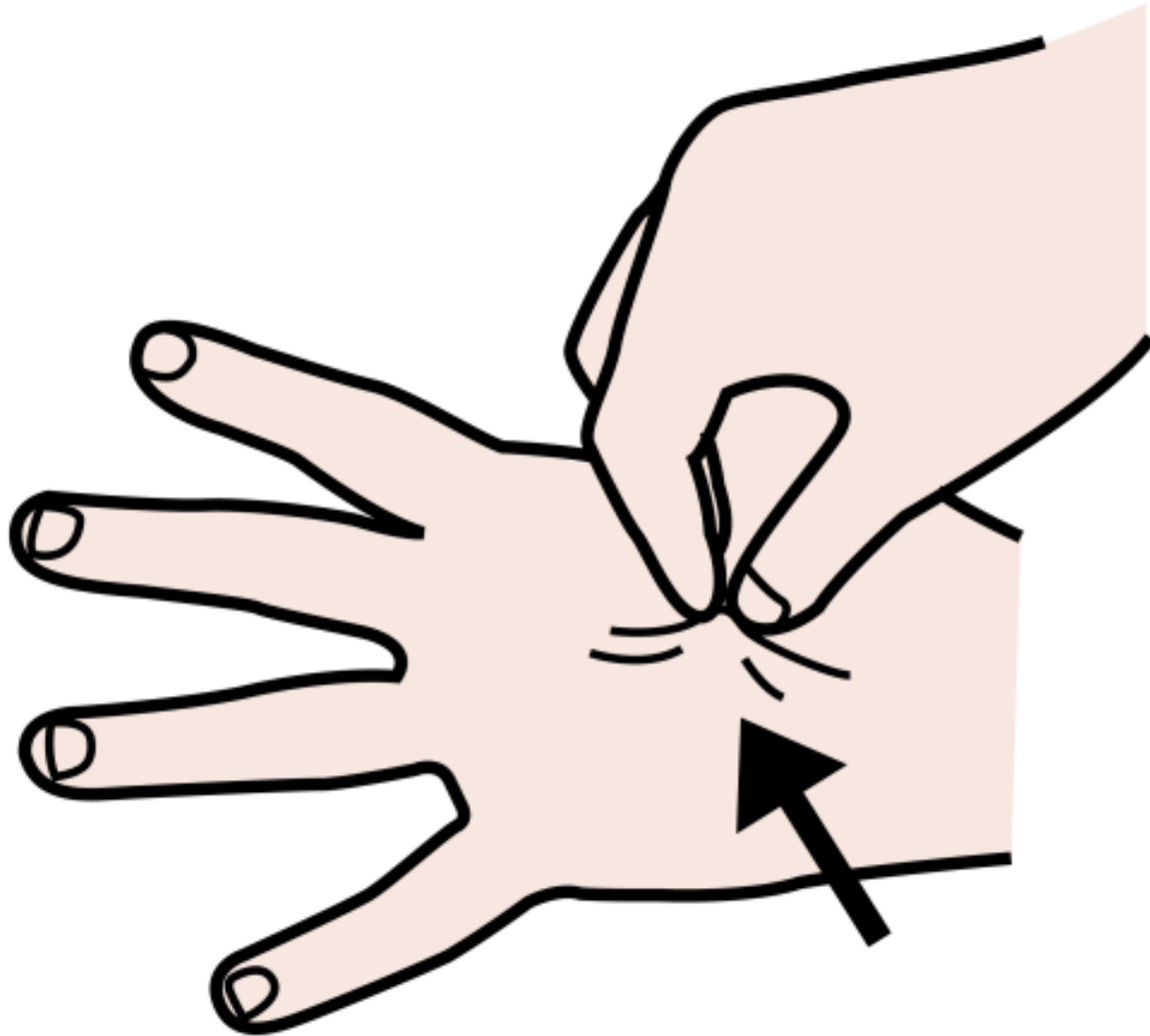


# IL TALLONE





# LA PELLE



Colegio: ATADES–C.C.E.E. San Martín De Porres

Autoras: Ana Isabel Álava y Rosa Asín

Traduzione: Anna Sodini

**Autor pictogramas:** Sergio Palao

**Procedencia:** <https://arasaac.org/>

**Licencia:** [CC \(BY-NC-SA\)](https://creativecommons.org/licenses/by-nc-sa/4.0/)